

Figure 1: Pedigree chart (created by authors)

Clinical findings

The physical examination of the patient revealed stunted growth, skeletal deformities of the lower limbs (genu varum), and facial dysmorphism (**Figure 2a**) characterized by a prominent forehead, craniotabes and hypertelorism with left eye convergence suggestive of strabismus (**Figure 2b**).

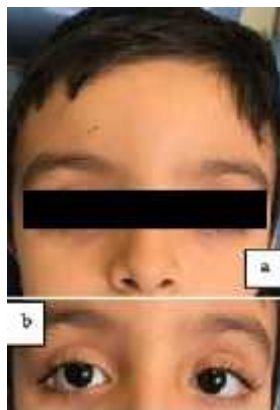


Figure 2: Frontal examination: **a.** facial dysmorphism, **b.** strabismus.

The endobuccal examination showed that the child had poor oral hygiene along with chronic marginal gingivitis and fistulized abscesses apically to the apparently healthy 51 and 61 teeth (**Figure 3**)

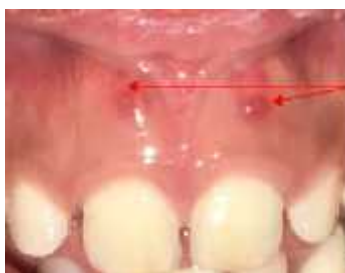

Figure 3: Intraoral examination: fistulized abscesses in the area of teeth 51 and 61

Timeline:

The child was under treatment for her systemic condition at the department of pediatric and had shown considerable improvement since then. As per his medical records, Vit-D supplementation was started initially to evaluate the patient's response to

the therapy; however, no improvement was noticed indicating the resistance to therapy. He had no other specific condition at the time of consultation. Before referral, he was previously admitted to a public dental hospital for the removal of the right mandibular second primary molar and received antibiotic treatment (amoxicillin) for 7 days.

Diagnostic assessment

A retro-alveolar radiography was performed as the hyperactivity of the patient did not allow the use of a panoramic radiograph. It indicated the presence of a large pulp cavity with elongated corn associated with a significantly reduced mineralized tissue thickness and a radiolucent image at the apical level of the 51 and 61 teeth (**Figure 4**).

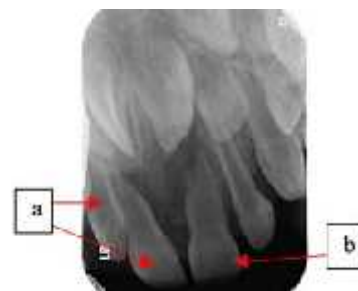

Figure 4: Radiological examination: **a.** large pulp cavity, **b.** reduced mineralized tissue thickness.

Diagnosis

The patient diagnosed with hypophosphatemic rickets, presented unsatisfactory hygiene and gingivitis. The diagnosis of chronic pulpal periodontal disease was retained for teeth 51 and 61, which had a poor prognosis.

Therapeutic intervention

The initial appointment was short and focused on the psychological approach to the child, aiming to establish a relationship of trust between him and the practitioner. Oral hygiene instructions were provided to the mother, emphasizing the importance of maintaining proper oral hygiene for her son, considering his overall health condition. On the next appointment, oral prophylaxis was done followed by

topical fluoride varnish application dose 22600 PPM. Then, surgical removal of the 51 and 61 teeth was performed under local anesthesia (2% lidocaine with 1:80000 epinephrine) on the third appointment followed by a prescription of 0.12% chlorhexidine solution.

Follow-up and outcome of interventions

The patient was seen one week later with an uneventful healing process. A regular follow-up program has been set up to preserve the remaining teeth until the eruption of the permanent teeth. These follow-up sessions will enable the prophylaxis program to be maintained, with fluoride applications to strengthen tooth structures and early detection of oral complications. The patient was then followed for a period of one year, with no signs of recurrence.

Patient's feedback

Both the patient and his mother were satisfied with the successful dental management and showed a positive reaction during the follow-up period.

Discussion

Hypophosphatemic rickets, also called familial hypophosphatemia, refractory rickets, or phosphate diabetes is a hereditary disorder of phosphorus metabolism marked by the resistance to vitamin D therapy [3]. Most cases are associated with an X-linked dominant mutant gene; however, autosomal recessive and rare sporadic forms have also been reported as in our case. The genetic abnormality underlying this condition results in a defective reabsorption of phosphate in the proximal renal tubule and the inadequate synthesis of vitamin D. This biochemical disorder has clinical, pathological, radiographic and dental consequences which are a direct result of a specific enzymatic disturbance [4,5]. The presented case shared common features with reported cases of hypophosphatemic rickets like craniotabes with frontal and occipital skull bossing, leading to an increased anteroposterior diameter of the skull, bowing of the legs, short stature, increased irritability and restlessness that alter quality of life [6-8]. Two-thirds of patients with hypophosphatemic rickets show characteristic dental and periodontal lesions, such as spontaneous periapical abscesses with fistulae that develop with no history of trauma or dental decay like in our case [9]. The teeth present enlarged pulps chambers with altered shape and morphology and prominent pulp horns into the tooth crown. They also present poor dentin mineralization, diminished lamina dura and bone loss [9,10]. These dental defects may predispose to pulp necrosis and periapical complications in these caries-free teeth that affect most of the patients. Hence, diffusion of bacterial

toxins through enamel and dentin that has undergone physiological attrition is inevitable. Moreover, the pulp is unable to resist bacterial invasion by laying down reparative dentin due to the rapid diffusion of toxins, to its increased fibrotic content and reduced number of regenerative cells (odontoblasts) [11]. These changes in teeth due to the systemic disease can occur in all teeth as any disturbances in mineral metabolism during odontogenesis can alter their development. However, the severity of the dental lesions, -particularly the extensions of the pulp horns to the dentino-enamel junction-, appear to be more pronounced in deciduous teeth; this may be attributed to the thinner and more permeable hard structures of deciduous teeth than the permanent dentition. The severity of the clinical and radiographic dental manifestations are also influenced by the type of teeth as to pre- or postnatal odontogenesis (as the prenatal period provides more favorable nutritional conditions than the postnatal period) [12]. This explain why in our case, the first primary molars (prenatal odontogenesis) remained intact while the second primary molar developed a peri apical abscess (postnatal odontogenesis). Considering the fact that the identification of this condition in children without a family history may be challenging since leg bowing become apparent after the child starts walking; and that the low glomerular filtration rate during infancy inhibits phosphaturia [2] and since these dental manifestations can be the initial indicators of the disease (as abscessed teeth with gingival fistulas without evidence of decay, fractures or attrition can all be seen at a very early stage of the disease), it is essential for every dental surgeon to be aware of these dental manifestations in order to refer the patient for appropriate diagnosis and medical care. Once the diagnosis has been made, dental treatment must be initiated and continued throughout the patient's life. A thorough clinical and radiological dental examination should be carried out on a regular basis (every three months) in order to intercept the dental sequelae of the pathology by implementing dental prophylaxis.

Conclusion

As early diagnosis vitamin-D-resistant rickets is crucial for successful outcomes, it is essential that dentists have a thorough understanding of the various associated dental manifestations and collaborate with other pediatric specialists, given the multisystemic nature of this disease, to offer optimal treatment options.

Patient consent: A written informed consent was signed by the patient's guardian (mother) for the publication of the current case report.

Competing interests: The authors declare no competing interest.

Conflicts of interest: There are no conflicts of interest.

Authors' contributions: Sarah Tabbai, Merieme Lferde and Hind Ramdi contributed to the design, analysis, interpretation of data, and writing of the manuscript. All the authors read and approved the final version of this manuscript.

References

1. Bitzan M, Goodyer PR. Hypophosphatemic Rickets. *Pediatr Clin North Am*. 2019; 66: 179–207.
2. Bender IB, Naidorf IJ. Dental observations in vitamin D-resistant rickets with special reference to periapical lesions. *J Endod*. 1985; 11 (11): 514-20.
3. Ruppe MD. X-Linked Hypophosphatemia. 2012 Feb 9 [Updated 2017 Apr 13]. In: Adam MP, Feldman J, Mirzaa GM, et al., Editors. *GeneReviews*® [Internet]. Seattle (WA): University of Washington, Seattle; 1993-2023.
4. Behrman RE. Familial hypophosphataemia. In: Behrman RE, Kleigman RM, Nelson W, Vaughan VC. *Textbook of Pediatrics*, 14th edn. Philadelphia: WB Saunders and Co., 1992: 1750±1751.
5. Glorieux FH. Hypophosphataemic vitamin D-resistant rickets. In: *Primer on the Metabolic Bone Diseases and Disorders of Mineral Metabolism*, 2nd edn New York: Raven Press, 1993: 279±282.
6. Emma F, Cappa M, Antoniazzi F, Bianchi ML, Chiodini I, Eller Vainicher C, Di Iorgi N, Maghnie M, Cassio A, Balsamo A, Baronio F, De Sanctis L, Tessaris D, Baroncelli GI, Mora S, Brandi ML, Weber G, D'Ausilio A, Lanati EP. X-linked hypophosphatemic rickets: An Italian Experts' Opinion Survey. *Ital J Pediatr* (2019) 45:67. doi: 10.1186/s13052-019-0654-6.
7. Carpenter TO. The Expanding Family of Hypophosphatemic Syndromes. *J Bone Miner Metab* (2012) 30:1–9. doi: 10.1007/s00774-011-0340-2.
8. Haffner D, Emma F, Eastwood DM, Duplan MB, Bacchetta J, Schnabel D, Wicart P, Bockenbauer D, Santos F, Levchenko E, Harvengt P, Kirchhoff M, Di Rocco F, Chaussain C, Brandi ML, Savendahl L, Briot K, Kamenicky P, Rejnmark L, Linglart A. Clinical practice recommendations for the diagnosis and management of X-linked hypophosphataemia. *Nat Rev Nephrol* (2019) 15:435–55. doi: 10.1038/s41581-019-0152-5.
9. Chaussain-Miller C, Sinding C, Wolikow M, Lasfargues JJ, Godeau G, Garabedian M. Dental Abnormalities in Patients With Familial Hypophosphatemic Vitamin D-Resistant Rickets: Prevention by Early Treatment With 1-Hydroxyvitamin D. *J Pediatr* (2003) 142:324–31. doi: 10.1067/mpd.2003.119
10. Baroncelli GI, Angiolini M, Ninni E, Galli V, Saggese R, Giuca MR. Prevalence and Pathogenesis of Dental and Periodontal Lesions in Children With X-linked Hypophosphatemic Rickets. *Eur J Paediatr Dent* (2006) 7:61–6.
11. Baroncelli Gi, Zampollo E, Manca M, Toschi B, Bertelloni S, Michelucci A, Isola A, Bulleri A, Peroni D, Giuca Mr. Pulp chamber features, prevalence of abscesses, disease severity, and PHEX mutation in X-linked hypophosphatemic rickets. *J Bone Miner Metab* (2021) 39:212–23. doi: 10.1007/s00774-020-01136-8.
12. Witkop, C.J.: Manifestations of Genetic Diseases in the Human Pulp, *Oral Surg*. 32~278-316, 1971.