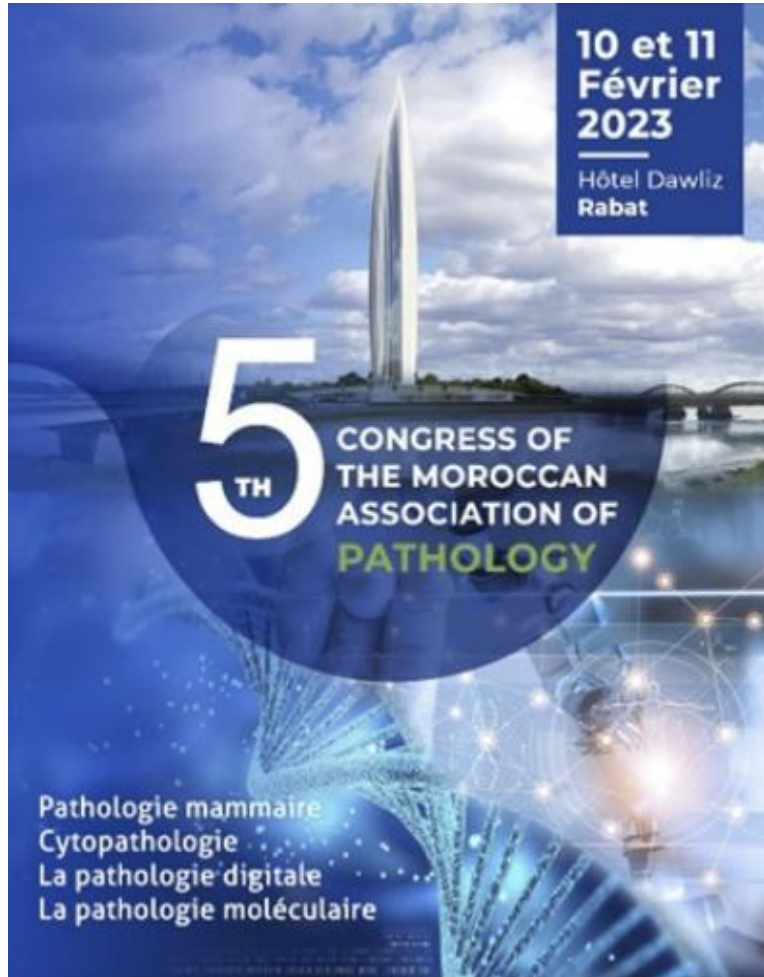



JMSR
Journal of Medical & Surgical Research

JMSR
Pathology
Beyond the Limits of the Human Eye

*This Special Issue is published
in partnership with
the Moroccan Association of Pathology*



and is a Part of JMSR Pathology Collection



The Editor-in-Chief of Journal of Medical and Surgical Research

Dr Younes Cherradi,

The Special Issue Peer-Review Boarding Comity:

<i>Dr Hicham El Attar</i>	<i>APC Labs, Casablanca, Morocco</i>
<i>Pr Basma El Khanoussi</i>	<i>National Institute of Oncology-Rabat, Morocco</i>
<i>Pr Hinde El Fatemi</i>	<i>CHU Hassan II Faculty of Medicine of Fez, Morocco</i>
<i>Pr Mehdi Karkouri</i>	<i>CHU Ibn Rochd, Faculty of Medicine Casablanca, Morocco</i>
<i>Pr Sanaa Abbaoui</i>	<i>Faculty of Medicine Agadir, Morocco</i>
<i>Pr Anas Belbachir</i>	<i>CHU Med VI, Faculty of Medicine Marrakech, Morocco</i>
<i>Pr Rais Hanane</i>	<i>CHU Med VI, Faculty of Medicine Marrakech, Morocco</i>
<i>Pr Regragui Meriem</i>	<i>CHU Ibn Rochd, Faculty of Medicine Casablanca, Morocco</i>
<i>Pr Mouna Khmou</i>	<i>National Institute of Oncology- Faculty of Medicine Rabat, Morocco</i>
<i>Dr Youssef Mahdi</i>	<i>National Institute of Oncology- Faculty of Medicine Rabat, Morocco</i>



JMSR Pathology Ab 1

Core Needle Biopsy Diagnosis of Fibroepithelial Lesions of the Breast in Moroccan Patients: Accuracy and Diagnostic Challenges.

Hasnae Ismaili^{1,2}, Layla Tahiri El Ousrouti¹, Abdelaziz Banani³, Moulay Abdelilah Malhouf³, Mustapha Maaroufi⁴, Hinde ElFatemi^{1,2}

¹Pathology Department, Hassan II^d, University Hospital, Fez, Morocco

²Biomedical & Translational Research Laboratory, Faculty of Medicine & Pharmacy, Hassan II^d University Hospital, Fez, Morocco

³Gynecology & obstetrics Department, University Hassan II^d, Hospital, Fez, Morocco

⁴Radiology Department, Hassan II^d University Hospital, Fez, Morocco

Corresponding Address: Hasnae Ismaili, Pathology Department, Hassan II^d University Hospital, Fez, Morocco.
E-mail: hasnae.i@hotmail.fr

Introduction: Breast fibroepithelial lesions (FELs) are biphasic neoplasms that consist of proliferative epithelial and stromal components. It comprises the spectrum of fibroadenomas (FAs) and phyllodes tumors (PTs). Core needle biopsy (CNB) provides a pathological basis, helping in diagnosing fibroepithelial lesions. However, the overlapping spectrum of histological appearance in FELs gives rise to diagnostic problems and may comprise the development of appropriate therapeutic plans. The purpose of this study is to analyze the accordance between CNB and excision diagnoses of FEL patients and evaluate the accuracy of CNB in preoperative diagnoses.

Methods: A retrospective review from the medical records of 68 female patients, who underwent preoperative CNB and surgical excision (SE), was performed at Hassan II^d University Hospital in 2022. **Results:** In our study, the concordant rate of diagnosis between CNB and SE is about 50%. Of the FAs diagnosed on CNB (44%), a total of 90% showed a complete match with surgical results and 10% revealed to be a PT. On CNB, 10% of the cases were diagnosed as PT and showed total concordance with the SE results. We concluded that 46% of the cases had FEL. On surgical excision, 60% revealed to be FA and 40% revealed to be PT.

Discussion: A multidisciplinary approach is a reliable strategy to distinguish between the different FELs. However, it is sometimes challenging, especially with some FA variants (e.g. cellular FA) which may resemble a phyllodes tumor. The main differential diagnosis of a malignant phyllode is spindle cell metaplastic carcinoma. The treatment is dissimilar. Therefore, it is imperative to differentiate between these lesions. **Conclusion:**

The assessment of histopathological features of FELs on CNB can be subjective. The overlapping spectrum of histological appearance in FELs and sampling limitations of CNB may need more investigation. Immunohistochemistry is helpful but limited. Recent advances in molecular characterization of FELs appear promising.

Keywords: Fibroepithelial lesion, core needle biopsy, breast

Competing interests: No competing interest among the authors.

A comparative table of various studies results

Latif et al. (2021)	A total of 28.8 % patients who had PT at excisional biopsy were diagnosed as FA on biopsy (vs. 10 % in our study).
Marcil et al. (2017)	The surgical excision of FEL diagnosed on CNB yields a pathological diagnosis of FA in 62.5 % and PT in 37.5 % (vs. 60 % FA and 40 % PT in our study).
Resetskova et al. (2010)	In 43 cases of excised FELs, 30 % were benign PTs, 53 % were FAs and 17% were benign cellular FELs (vs. 60% FA and 40 % PT in our study).

FELs: Fibroepithelial lesions; FAs: fibroadenomas; PTs: phyllodes tumors; CNB: Core needle biopsy

References

- Maliha Latif, Asif Loya, Maryam Hameed, Usman Hassan, Sajid Mushtaq, Mudassar Hussain. *Diagnosis on Excision Biopsy of Breast Tissues Labeled As Fibroepithelial Tumors on Trucut Samples in a Developing Country. Cureus* 2021;13 (9):e18111
- Gabriel Marcil, Stephanie Wong, Nora Trabulsi, Alexandra Allard-Coutu, Armen Parsyan, Atilla Omeroglu, Gulbeyaz Atinel, Benoit Mesurole, Sarkis Meterissian. *Fibroepithelial breast lesions diagnosed by core needle biopsy demonstrate a moderate rate of upstaging to phyllodes tumors. Am J Surg* 2017; 214(2):318-322. doi: 10.1016/j.amjsurg.2016.12.017
- Erika Resetskova, Laila Khazai, Constance T Albarracin, Elsa Arribas. *Clinical and radiologic data and core needle biopsy findings should dictate management of cellular fibroepithelial tumors of the breast. Breast J* 2010; 16(6):573-80. doi: 10.1111/j.1524-4741.2010.01013.x. PMID: 21070433.

JMSR Pathology Ab 2

Clinicopathologic Analysis of 169 Cases of Cutaneous Adnexal Tumors in Moroccan patients: A Retrospective Study

S. Moqran¹, L. Tahiri Elousrouti¹, S. Elloudi², Fz. El mernissi², N. Elouatassi³, Mn. Elalami³, L. Chbani¹, H. El-Fatemi¹, N. Hammam¹

1- Pathology department, University hospital Hassan II, Morocco

2- Dermatology department, University hospital Hassan II, Morocco

3- Department of Otorhinolaryngology, University hospital Hassan II, Morocco

Corresponding address: Sanae Moqran, Pathology Department, University hospital Hassan II^d, Fez, Morocco.
E-mail: sanaemkr@gmail.com. **ORCID ID:** <https://orcid.org/0009000041378139>

Background and objectives: Adnexal tumors (ATs) are a heterogeneous entity of primary skin tumors, rarely malignant. Their diagnosis represents a real challenge due to their polymorphism and the locoregional aggressiveness of adnexal carcinomas with their metastatic potential (1). This study aims to elucidate the morphological and epidemiological characteristics of these tumors through a series of Moroccan patients and to compare them with other series in the literature. **Methods:** A retrospective study was conducted over a period of 10 years (2013–2022), including all adnexal tumors of skin diagnosed in the Department of Pathology, University hospital Hassan II of Fez, Morocco. The histological study was performed on formalin-fixed

and paraffin-embedded tissue sections. The diagnosis was essentially morphological. Special staining or immunohistochemical complement was rarely used. **Results:** A total number of cases that was diagnosed as ATs were 169. There were 135 benign tumors (80%) and 34 malignant tumors (20%). A female predominance was noted with a sex ratio M/F of 0.72. The mean age was 49 yr (5yr–90yr). Most of the cases were in the age group between the 4th and 5th decades (51–60 yr (32/169 cases)). The head and neck are the most often affected areas (74.6%). About 44% of the tumors displayed sweat gland differentiation, 44% hair follicle differentiation and 12% of the tumors were sebaceous gland tumors. Tumors with follicular differentiation were predominant among adnexal carcinomas (58%). Pilomatricoma (16.6%) was the most prevalent tumor of all ATs, followed by chondroid syringoma (13%). Sebaceous Carcinoma (5.6%) was the most common malignant adnexal tumor. The detailed clinicopathological data are shown in the Table. All of our patients have benefited from a surgical procedure for the treatment of cutaneous adnexal carcinomas. Only 4 patients have been recommended for adjuvant radiotherapy. Following up with our patients allowed us to identify a recurrence in one case in the form of lymph node metastasis and a parotid metastasis in another. **Conclusion:** Our findings generally concur with those found in the literature (Omar A.M.R.M et al. 2022), with the exception of the frequency of carcinomas with follicular origin rather than those with sweat gland origin in other series (*Battistella M et al. 2022; El Ochi et al. 2015; Kooki C et al. 2021*).

Keywords: Benign; Malignant; Histopathology; Cutaneous adnexal tumor; Morocco.

Table: Clinicopathologic features of studied cutaneous adnexal tumors.

	mean age	Sex ratio (M/F)	Localisation
Benign tumors:			
Chondroid Syringoma : 22 cases	34 years	1.75	Head and neck (95%)
Hidrocystoma : 15 cases	42 years	1.5	Head and neck (73%)
Syringocystadénoma papillifère : 8 cases	43 years	0.4	Head and neck (100%)
Hidradénome nodulaire : 4 cases	51 years	4 women	Extremities (75%)
Syringoma : 6 cases	47 years	0.5	Head and neck (83%)
Poroma : 4 cases	52 years	0.33	Head and neck (50%) Extremities (50%)
Sweat gland differentiation : 75 cases (45%)			
Cylindroma : 3 cases	46 years	3 women	Head and neck (100%)
Hidradenoma Papilliferum : 3 cases	43 years	3 women	Genital tract (100%)
Hidradenoma : 3 cases	57 years	1.5	Genital tract (67%)
Spiradenoma : 2 cases	33 years	1	Head and neck (100%)
Syringofibroadenoma : 1 case	65 years	1 woman	Extremities
Malignant tumors :			
Porocarcinoma : 2 cases	66 years	1	Head and neck (50%) Extremities (50%)
Micrcystic adnexal carcinoma : 1 case	69 years	1 man	Head and neck
Syringoid eccrine carcinoma : 1 case	65 years	1 woman	Head and neck

Hair follicle differentiation: 74 cases (43%)	Benign tumors:			
	Pilomatricoma : 28 cases	24 years	0.64	Extremities (72%)
	Trichoblastoma : 20 cases	60 years	0.81	Head and neck (90%)
	Trichilemmoma : 3 cases	41 years	2	Head and neck (67%)
	Trichofolliculoma : 2 cases	49 years	1	Head and neck (100%)
	follicular poroma : 1 case	21 years	1 man	Head and neck
	Malignant tumors :			
	Proliferating trichilemmal tumor : 9 cases	54 years	0.12	Head and neck (89%)
	Trichilemmal carcinoma : 6 cases	48 years	0.5	Head and neck (67%)
	Trichoblastic Carcinoma : 3 cases	61 years	1	Head and neck (100%)
Sebaceous gland differentiation: 20 cases (12%)	Pilomatrix carcinoma : 1 case	75 years	1 woman	Head and neck
	Malignant Melanocytic Matricoma : 1 case	86 years	1 woman	Head and neck
	Benign tumors:			
	Sebaceous Hyperplasia : 6 cases	76 years	3	Head and neck (100%)
	Sebaceous Adenoma : 4 cases	53 years	1	Head and neck (100%)
Total : 169 cases	Malignant tumors :			
	Sebaceous Carcinoma : 10 cases	67 years	0.66	Head and neck (90%)
	Benign tumors: 135 (79.9%)	46 years	0.77	Head and neck (66%)
	Malignant tumors: 34 (20.1%)	63 years	0.54	Head and neck (85%)

References

Kaur K, Gupta K, Hemrajani D, Yadav A, Mangal K. *Histopathological Analysis of Skin Adnexal Tumors: A Three Year Study of 110 Cases at A Tertiary Care Center. Indian J Dermatol.* 2017; 62(4):400-406. doi: 10.4103/ijd.IJD_380_16. PMID: 28794552; PMCID: PMC5527722.

Omar A., Nisreen A. *Four years retrospective study of skin adnexal tumors: Histomorphology and special stain study. International Journal of Medical Science and Public Health.* 2020 Apr; 9(4): 273-279

Battistella M, Balme B, Jullie ML, Zimmermann U, Carlotti A, Crinquette M, Frouin E, Macagno N, Ortonne N, Lamant L, de la Fouchardiere A, Aubriot-Lorton MH, Durand L, Josselin N, Franck F, Chatelain D, Lemasson G, Algros MP, Durlach A, Machet MC, Courville P, Osio A, Seris A, Mortier L, Jouary T, Cribier B; CARADERM network. *Impact of expert pathology review in skin adnexal carcinoma diagnosis: Analysis of 2573 patients from the French CARADERM network. Eur J Cancer.* 2022; 163: 211-221. doi: 10.1016/j.ejca.2021.11.027. PMID: 35090811.

El Ochi MR, Boudhas A, Allaoui M, Rharrassi I, Chahdi H, Al Bouzidi A, Oukabli M. *Les tumeurs annexielles cutanées: étude anatomopathologique à propos de 96 cas [Skin adnexal tumors: Histological study about 96 cases]. Pan Afr Med J.* 2015; 20:389. doi: 10.11604/pamj.2015.20.389.6202. PMID: 26185579; PMCID: PMC4499321.

Chaima Kouki, Mariem Amouri, Fatma Hammemi, Emna Bahloul, Rim Kallel, Khadija Sellami, Madiha Mssedi, Tahya Boudawara, Hamida Turki . *Les tumeurs annexielles: étude monocentrique de 248 cas. Annales de Dermatologie et de Vénérologie-FMC,* 2021, 1.8: A288-A289.

JMSR Pathology Ab 3

Granulomatous Mycosis Fungoides: Report of Three Cases and Literature Review.

L. Benbella¹, I. Elouarith¹, S. Sassi¹, O. Essadeq², Z. Loubaris², F. Zouaidia¹, A. Jahid¹, Z. Bernoussi¹, K. Znati¹

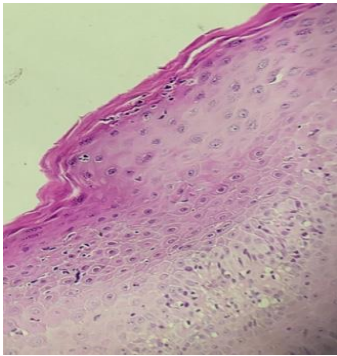
¹ Department of Pathological Anatomy, Ibn Sina Hospital, Faculty of Medicine and Pharmacy, Mohammed V University, Rabat, Morocco

² Department of Dermatology, Ibn Sina Hospital, Faculty of Medicine and Pharmacy, Mohammed V University, Rabat, Morocco

Corresponding address: Leila Benbella, Department of Pathology, Ibn Sina Hospital, Rabat, Morocco. **E-mail:** Benleila993@gmail.com

Introduction: Granulomatous mycosis fungoides (GMF) is a rare form of cutaneous T-cell lymphoma which is a major diagnostic challenge. The objective of this study is to relate the clinical and pathological aspects of this condition and to discuss its differential diagnoses. **Case Reports:** The cases included three patients with GMF, admitted to the Dermatology Department of Ibn Sina Hospital in Rabat. The first one is 35-year-old female patient, diabetic, admitted for the management of a slowly growing erythematous plaque formed on the abdomen, which rapidly ulcerated. The second one is 46-year-old female, with no medical history, presented with erythematous plaque of the neck, evolving for 3 weeks. The 3rd case corresponds to a 63-year-old male patient, treated since 2013 for mycosis fungoides. The histological study showed the same findings in the three patients, including the exocytosis of atypical lymphocytes in the epidermis and the presence of authentic epithelioid granulomas in the underlying dermis. The immunohistochemical study showed a negative staining of the anti-CD5 antibody (1st case), the anti-CD7 antibody (2nd

case) and the anti-CD2 antibody (3rd case). The anti-CD30 antibody was negative in all three cases. **Comment:** Granulomatous MF, originally described in 1970 (Gutte *et al.*, 2020; Kempf *et al.*, 2008), is a rare histological form, constituting 6.3% of MF described in the literature (Li *et al.*, 2013). The clinical findings are non-specific and the diagnosis is purely anatomopathological (Kempf *et al.*, 2008). Histologically, the signs of classical MF are present, namely atypical lymphocytes in the dermis with epidermotropism. The granulomas are sarcoid-like, mixed with Langhans giant cells. Conclusion: Granulomatous mycosis fungoides (GMF) is a rare histological form of cutaneous T-cell lymphoma that can histologically mimic infectious or inflammatory dermatosis and cause a delay in diagnosis. Anatomoclinical correlation, good morphological analysis, and immunohistochemical study aid in the diagnosis.



HE staining showing the exocytosis of atypical lymphocytes in the epidermis (left) and the presence of authentic epithelioid granulomas in the underlying dermis (right)

Keywords: Mycosis fungoides, T-cell lymphoma, granulomas

Conflicts of interest: There are no competing interests or funding to declare.

References

- Gutte, R., Kharkar, V., Mahajan, S., Chikhalkar, S., and Khopkar, U. (2010). Granulomatous mycosis fungoides with hypohidrosis mimicking lepromatous leprosy. *Indian Journal of Dermatology, Venereology and Leprology*, 76, 686-690
- Kempf, W., Ostheeren-Michaelis, S., Paulli, M., Lucioni, M., Wechsler, J., and Audring, H. A. L. (2008). Granulomatous mycosis fungoides and granulomatous slack skin. *Archives of Dermatology*, 144, 1609-1617.
- Li, J. Y., Pulitzer, M. P., Myskowski, P. L., *et al.* (2013). A case-control study of clinicopathologic features, prognosis, and therapeutic responses in patients with granulomatous mycosis fungoides. *Journal of the American Academy of Dermatology*, 69, 366-374.

JMSR Pathology Ab 4

Pre-Analytical Performance in Surgical Pathology: Improvement of the Fixation Technique at Ibn Rochd University Hospital of Casablanca-Morocco

Nadia Anibat^{1,2}, Mohamed Belcaid¹, Abderrahmane Mellouki², Oussama Aazzane¹, Abdeljalil Rezzaki², Meryem Keballi², Laila Zoubir², Naima Khilil³, Mehdi Karkouri^{1,2},

¹ Laboratory of Cellular & Molecular Pathology, Faculty of Medicine & Pharmacy, Hassan II University, Casablanca, Morocco. ² Pathology Department, Ibn Rochd University Hospital, Casablanca, Morocco.

³ Laboratory of Chemistry-Biochemistry, Environment, Nutrition & Health "LC-BENS", Faculty of Medicine & Pharmacy, Casablanca, Morocco.

Corresponding address: Nadia Anibat, Pathology Department, Ibn Rochd University Hospital of Casablanca, Morocco. **E-mail:**

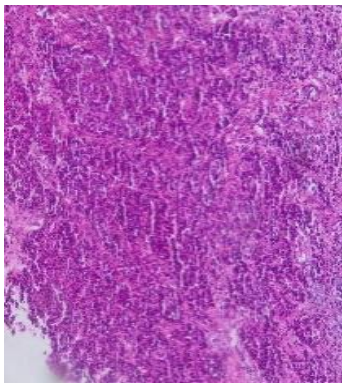
Nadia.anibat09@gmail.com

Background: Pathologists play a crucial role in the management of patients, especially in the case of tumor diseases. In order to achieve these missions, an adequate course of the pre-analytical phase with all its steps is critical. Fixation is a fundamental part of the pre-analytical process, and it is used to protect tissue from decay, making the morphological analysis of tissue and cells possible.

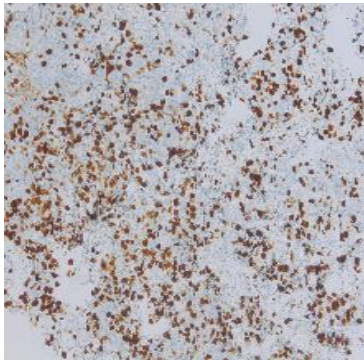
Objective: To improve the fixation process in a central department of Pathology, serving four university hospitals, and to discuss the benefits and drawbacks of each protocol. **Methods:** We carried out a prospective study in the department of Pathology of the Ibn Rochd University Hospital, Casablanca, Morocco. We evaluated the quality of fixation by buffered formalin compared to unbuffered formalin on surgical breast specimens collected from the Oncology-gynecology Department over a period of three months. We evaluated slides reading and current recommendations. **Results:** A total of 145 specimens were examined and five pathologists participated in this study. Each case was analyzed by two pathologists. We summarized our results in the table below. **Conclusion:** The use of buffered formalin allowed a stable and reproducible fixation, a better preservation tissue, a relatively short period of fixation and better morphological analysis.

Table: Summary of the main findings

Specific processes		Specific criteria	Used Fixers	
			Unbuffered formalin	Buffered formalin (ph=7.1)
Quality of cuts		Adequate thickness	B	A
		Presence/absence of tears, creases, streaks, dye stains, delaminations	C	B
		Presence/absence of contamination	B	A
		Montage	B	A
Quality of routine staining	Nuclear components	Clear and blue/purple chromatin	B	A
		Well identified nucleolus	B	A
		Well defined nuclear membrane	B	A
	Cytoplasmic features	Well delimited cytoplasm	B	A
		Well defined cytoplasmic granules	B	A
		Well defined mucus	B	A
	Extracellular matrix components	Bright red hematias	B	A
		Quality of fibers	B	A



Breast HE X200



Breast Ki-67X200

Keywords: Pre-analytic, quality, fixation process, buffered formalin, Morocco.

Conflicts of interest: None

References:

1. Directives de qualité SPath –Cancer sein Version 2017. ISO NF15189 version 2012. ISO 20166.4:2021(fr), Analyses de diagnostic moléculaire in vitro.
2. William, J., H. and Wilson, B. A. (2014). Tissue fixation and the effect of molecular fixatives on downstream. Staining Procedures. doi: 10.1016/j.ymeth.2014.01.022.

JMSR Pathology Ab 5

TDT Positive in Blastic Oermal nitrate: Think to Blastic Plasmacytoid Oendritic Cell Neoplasm

Asmaa El Kebir¹, Farida Marnissi¹, Meriem Regragui¹, Asmae Mazzi¹, Samira Benayad¹, Nisrine Bennani - Guebessi¹, Mehdi Karkouri¹

¹Department of anatomical pathology, Ibn Rochd University Hospital Center, Hassan II University of Casablanca, Faculty of Medicine and Pharmacy, Casablanca, Morocco

Corresponding address: Sara Chaabi, MD, Department of anatomical pathology, Ibn Rochd University Hospital Center, Hassan II University of Casablanca, Faculty of Medicine and Pharmacy, Casablanca, Morocco , **E-mail:** Sara.chaabi.chaabi@gmail.com; **ORCID ID:** <https://orcid.org/0009-0009-9479-2507>

Background: Terminal deoxynucleotidyl transferase (TdT) is a DNA polymerase expressed in lymphoblastic lymphomas/leukemias but also in other undifferentiated tumors. The expression of TdT in a blastic dermal infiltrate may constitute a diagnostic pitfall. We present here a case diagnosed at our institution illustrating this diagnostic difficulty. **Report Case:** We reported the case of an 81-year-old man, with no particular medical history, who had consulted for a purplish nodular dorsal mass accompanied by several diffuse infiltrated papular lesions that had evolved over several months. The biopsy showed a diffuse tumor infiltrate in the dermis, made of medium- sized cells with reduced cytoplasm and dense chromatin and separated from the epidermis by a grenz zone (**Figure 1**). The initial immunohistochemical study showed absence of CD3, CD8, and CD20 expression and expression of CD4, CD56 and TdT (**Figure 2**). Other lymphoid markers were requested to rule out lymphoma/lymphoblastic leukemia (PAX5, CD79a, CD5) as well as myeloid markers to rule out myelomonocytic leukemia (MPO, CD34, CD68,

CD15), cytotoxic markers to rule out NK lymphoma (granzyme B and TIA1) and epithelial and neuroendocrine markers to rule out Merkel carcinoma. These markers were all negative, pointing to a blastic plasmacytoid dendritic cell neoplasm. **Conclusion:** Blastic plasmacytoid dendritic cell neoplasm (BPDCN) is a rare hematologic malignancy with usually poor outcomes and high risk of progression to acute leukemia. Histological diagnosis is challenging and immunohistochemical analysis is mandatory. This entity represents a diagnostic challenge for pathologists given its rarity and possible terminal deoxynucleotidyl transferase (TdT) expression.

Keywords: Terminal deoxynucleotidyl transferase, blastic dermal infiltrate

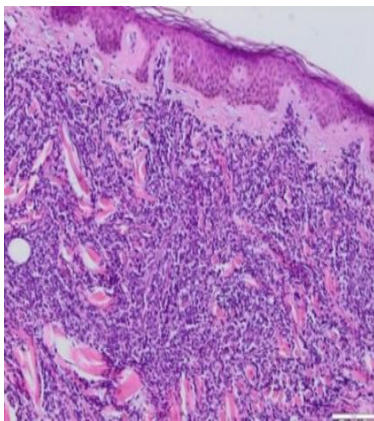


Figure 1: HEx200, diffuse tumor infiltrate in the dermis separated from the epidermis by a grenz zone.

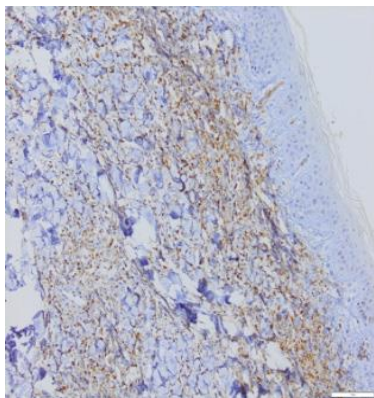


Figure 2: Tdtx200

References

1. Lim, M. S., Lemmert, K., and Enjeti, A. (2016). Blastic plasmacytoid dendritic cell neoplasm (BPDCN): a rare entity. *BMJ Case Reports*, doi: 10.1136/bcr-2015-214093. Patel,
2. J. L. et al. (2011). An unusual case of cutaneous blastic plasmacytoid dendritic cell neoplasm with concomitant B-cell lymphoproliferative disorder. *The American Journal of Dermatopathology*, 33(3), e31-e36. doi: 10.1097/dad.0b013e3181de9ce0.
3. Wechsler, J. et al. (Pathologie cutanée tumorale 2 édition, Sauramps Médical. WHO Classification of skin Tumors, 4th Edition.

JMSR Pathology Ab 6

The Clinicopathological Features and Prognostic Impact of HER 2-Low Breast Tumors Subtype in Moroccan Context: A New Opportunity for Untreated Patients

Layla Tahiri Elousrouti^{1,2}, Sanaa Gamrani², Laila Akhouayri^{3,4}, Mehdi Karkouri^{3,4}, Hinde El Fatemi^{1,2}

1-Department of Pathology, Hassan IId University Hospital, Fez, Morocco.

2- Biomedical and Translational Research Laboratory, Faculty of Medicine & Pharmacy, Sidi Mohamed Ben Abdellah University, Fez, Morocco.

3- Department of Pathology, Ibn Rochd University Hospital, Casablanca, Morocco

4-Biomedical Sciences, Genetics & Molecular Biology Laboratory, Faculty of Medicine and Pharmacy, Hassan II^d University, Casablanca, Morocco.

Corresponding address: Layla Tahiri Elousrouti, MD, Department of Pathology, Hassan II^d University Hospital, Fez, Morocco. **ORCID ID:** <https://orcid.org/0000000228487549>; **E-mail:** Layla.tahirielousrouti@usmba.ac.ma.

Introduction: The emergence of a new tumor entity called HER2-low breast cancer leads us to reconsider therapeutic indications in patients whose tumors were considered as HER2-negative. HER2-Low subtype was defined as HER2 1+ and HER2 2+ FISH not amplified (Marchiò et al. 2021). The development of antibody-drug conjugates (ADCs) allows using HER2 as a vector of a cytotoxic drug with significant clinical efficacy and less side effects in breast cancer with HER2 low expression (Agostinetto et al. 2021). Herein, we aimed to evaluate the differences in clinicopathological characteristics and prognostic factors between HER2-Low breast carcinoma and those with HER2-negative cancer, according to HR profile. **Methods:** We conducted a 10-years bicentric cohort study on 1955 invasive breast tumors of Moroccan patients, collected at two Moroccan centers between 2012 and 2022. **Results:** Out of 1955 BC patients, 49.3% were classified as HER2-Low; of which 80.7% were hormone receptors positive. The clinicopathological features indicate that HER2-Low subtype behave much more like HER2-positive than HER2-negative tumors. The survival analysis showed that the HER2-Low subtype-belonging patients present significantly the poorest prognosis in disease free survival ($p=0,003$). Hormonal dependent tumors show a significant difference according to HER2 subtypes in disease free survival (DFS) ($p<0,001$). Moreover, patients with HR+/HER2-Low tumors subgroup present a significantly good prognosis in overall survival (OS) compared to the ones with hormonal negative tumors ($p =0.008$). **Discussion:** The introduction of the concept of HER2-low BC has extended the benefit observed with novel anti-HER2 agents to a much larger number of patients with BC

from 15% to 70% (Marchiò *et al.* 2021). Several studies reported incidences of 31% to 59.7%, based on data from The Cancer Genome Atlas and clinical trial dataset. HER2-low tumors were frequently found within HR-positive BCs compared to HR-negative cancers (Schettini *et al.* 2021). These findings are strongly similar to our results. Early and metastatic BCs characterized by a larger tumor size, more LN metastasis and slightly higher grade in her2-low BC compared to her2 negative, which is similar to our study. According to PAM50 intrinsic classifier, there was a significant difference between her2-low and her2 zero in HR negative group while there is no difference in HR positive group, in particular, HER2 enriched represented 13.7% in HR-/HER2 Low vs 1.6% IN HER2-ZERO (Schettini *et al.* 2021). This intrinsic heterogeneity of HER2-Low group, reflected already on clinical outcome, highlights the importance of considering HR status in the HER2-low BCs (Zhang H & Peng Y. 2022). **Conclusion:** HER2-low breast cancer is now distinct subgroup of BCs of which is necessary to consider the HR status. To select HER2-low patients, pathologist must adhere to guidelines and maintain accurate performance and consistent interpretation of test results. Finally, Future prospective analysis and deeper understanding of HER2-low breast cancer requires to allow personalized treatment and avoid under or over treatment.

Keywords: HER2 low, breast cancer, hormone receptors, survival; Morocco.

References

- Marchiò C, Annaratone L, Marques A, Casorzo L, Berrino E, Sapino A. Evolving concepts in HER2 evaluation in breast cancer: Heterogeneity, HER2-low carcinomas and beyond. *Semin Cancer Biol.* 2021; 72: 123-135. doi: 10.1016/j.semcancer.2020.02.016.
- Agostinetto E, Rediti M, Fimereli D, Debien V, Piccart M, Aftimos P, Sotiriou C, de Azambuja E. HER2-Low Breast Cancer: Molecular Characteristics and Prognosis. *Cancers (Basel).* 2021;13 (11):2824. doi: 10.3390/cancers13112824.
- Schettini F, Chic N, Brasó-Maristany F, Paré L, Pascual T, Conte B, Martínez-Sáez O, Adamo B, Vidal M, Barnadas E, Fernández-Martínez A, González-Farre B, Sanfeliu E, Cejalvo JM, Perrone G, Sabarese G, Zalfa F, Peg V, Fasani R, Villagrasa P, Gavilá J, Barrios CH, Lluch A, Martín M, Locci M, De Placido S, Prat A. Clinical, pathological, and PAM50 gene expression features of HER2-low breast cancer. *NPJ Breast Cancer.* 2021; 7(1):1. doi: 10.1038/s41523-020-00208-2.
- Zhang H & Peng Y. Current Biological, Pathological and Clinical Landscape of HER2-Low Breast Cancer. *Cancers (Basel).* 2022; 15 (1):126. doi: 10.3390/cancers15010126.

JMSR Pathology Ab 7

The Prognosis and Predictive Value of Estrogen Negative/Progesteron Positive (ER-/PR+) Phenotype in Moroccan Patients

Layla Tahiri Elousrouti, Sanae Gamrani, Hinde El Fatemi.

Department of Pathology, Hassan II^d University Hospital, Fez, Morocco; Biomedical & Translational Research Laboratory, Faculty of Medicine and Pharmacy, SMBA University, Fez, Morocco.

Corresponding address: Layla Tahiri Elousrouti, MD, Department of Pathology, Hassan II^d University Hospital, Fez, Morocco; **E-mail:**

Layla.tahiri@elousrouti.usmba.ac.ma **ORCID ID:** <https://orcid.org/0000000228487549>

Background: Breast cancer (BC) is a serious public health problem worldwide and is currently the most common cancer overall. Its endocrine therapy is related to the expression of steroid hormones (ER/PR). BC can be presented under multiple profiles of steroid hormones. There are only 2-8% of breast cancers that express only PR (ER-/PR+), which is an abnormal phenotype, and their behaviors and outcomes are less well-known. **Methods:** We collected a large and well-characterized database of primary BC from 2012 to 2019, including 1159 cases. These cases were divided according to ER and PR expression, we focused ER-/PR+/HER2+ and ER-/PR+/HER2- subgroups, to highlight their clinicopathologic features. **Results:** A total of 94 patients (8%) had ER-/PR+ profile, while 676 (58.4%) had ER+/PR+, 88 (7.6%) had ER+/PR-, and 164 (14.2%) had ER-/PR- profile. The ER-/PR+ group was statistically correlated with a high risk of recurrence and death in midway between the double negative and double-positive HR. According to HER2 status, a low DFS was observed in patients ER-/PR+/HER2-, which was closer to the DFS of TNBC cases but worse than ER+/PR any. On the other hand, the ER-/PR+/HER2+ showed a poorer DFS closer to the HER2+ subgroup between TNBC and ER+/PR any. The clinicopathological features of the ER-/PR+/HER2- and ER-/PR+ HER2+ have distinguished the patients into two groups with a difference in some clinicopathological characteristics: both groups had closer OS estimation, which was worse than ER-/PR any and better than TNBC and HER2. On the other hand, the ER-/PR+/HER2+ seems to increase the risk of death more than ER-/PR+/HER2- in comparison with ER+/PR any. **Discussion:** In our study, 8% of patients had presented the ER-/PR+ phenotype; this is consistent with the previously published cohort using ER and PR IHC. Our findings are similar to those already published such as younger age at diagnosis, poorly differentiated tumor and larger tumor size. On the other side, the separation into intrinsic subtypes by PAM50 test revealed that the vast majority of cases were of the basal subtype (53-65%), followed by the Luminal A subtype (15-

27%). It shares molecular features with TNBC. 90% of ER (-)/PR(+) tumors are characterized by low predicted endocrine sensitivity by the sensitivity to endocrine therapy (SET) gene signature, especially in "high-risk" cancers. **Conclusion:** ER-/PR+ BCs really exist and it's different from other subgroups BCs, its clinical molecular feature and behaviors midway between those of double positive and double negative, moreover, this distinction seems more important in the subgroup HER2 negative which is slightly similar to TNBC. So the question is treat or not treat with ET single PR+ BC, the response to this requires prospective studies and clinical trials in order to optimize the breast cancer's treatment in the era of precision medicine.

Keywords: breast cancer, immunohistochemistry, estrogen negative/progesterone positive phenotype, prognosis; Morocco.

References

1. Ahmed, S. S., 'ike, A. A., Zhang, K., Chun, J., Lim, T., and Tan, P. H. (2017). Clinicopathological characteristics of estrogen receptor negative, progesterone receptor positive breast cancers: re-evaluating subsets within this group. *Journal of Clinical Pathology*, 70, 320–326.
2. Kunc, M., Biernat, W., and Senkus-Konefka, E. (2018). Estrogen receptor-negative progesterone receptor-positive breast cancer -Nobody's land or just an artifact? *Cancer Treatment Reviews*, 67, 78–87. doi: 10.1016/j.ctrv.2018.05.005.
3. Onitilo, A. A., Engel, J., Joseph, A. O., and Li, Y. H. (2021). Is estrogen receptor-negative/progesterone receptor-positive (ER-/PR+) a real pathological entity? *Eccancer Medical Science*, 15, 1278. doi: 10.3332/ecancer.2021.1278.
4. Rakha, E. A., El-Sayed, M. E., Green, A. R. et al. (2007). Biologic and clinical characteristics of breast cancer with single hormone receptor-positive phenotype. *Journal of Clinical Oncology*, 25(30), 4772–4778.
5. Yu, K. D., Jiang, Y. Z., Hao, S., and Shao, Z. M. (2015). Molecular essence and endocrine responsiveness of estrogen receptor-negative, progesterone receptor-positive, and HER2-negative breast cancer. *BMC Medicine*, 13, 254. doi: 10.1186/s12916-015-0496-z.

JMSR Pathology Ab 8

What is the Prognostic Impact of Necrosis in Colic Adenocarcinoma? The Experience of Pathology Department in Fez- Morocco.

Abdoulaye Biyou Habsatou¹, Souhaila El yaagoubi¹, Mohammed Omari³, Laila Tahiri^{1,2}, Nawel Hammas^{1,2}, Laila Chbani^{1,2}

¹Department of Pathological Anatomy & Cytology, CHU Hassan II, Fez, Morocco

²Faculty of Medicine and Pharmacy, Sidi Mohamed Ben Abdallah University, Fez, Morocco

³Laboratory of Epidemiology and Clinical Research, SMBA University, Fez, Morocco

Corresponding address: Abdoulaye Biyou Habsatou, MD, Department of Pathology & Cytology, CHU Hassan II, Fez, Morocco. **ORCID ID:** orcid.org/0009000836082366; **E-mail:** habsatou.abdoulayebivou@usmba.ac.ma

Background: Colon cancer is a real public health problem (Keum and Giovannucci, 2019). Tumor necrosis has been proposed as an independent prognostic marker for colon cancer following a number of similar studies reporting necrosis as a marker of poor prognosis in renal, breast and lung carcinomas (Pollheimer et al., 2010; Richards et al., 2012). The mechanisms underlying the relationship between necrosis and cancer survival, however, are unclear (Richards et al., 2012). The aim of this work is to analyze the prognostic value of tumor necrosis in colonic adenocarcinomas by comparing our results with those of the literature. **Methods:** This is a retrospective study of 100 cases of colonic adenocarcinoma diagnosed in the pathological anatomy and cytology department of CHU Hassan II in FES. The diagnosis was made after histological study. Tumor sections were made and the presence of necrosis was split into two groups: more than 50% or less than 50%. Correlations have been made between the presence of necrosis and its extent and the various histoprognostic factors and patient survival. Statistical analysis was performed using SPSS software and a correlation is considered significant if $p < 0.05$. Overall survival was assessed using the Kaplan Meier method. Results: Results: A total of 100 cases of colonic adenocarcinoma were included in our study. The mean age was 57 years, with extremes of 29 and 89 years. There was a slight male predominance, with a sex ratio (M/F) of 1.77. The most frequent location was the right colon. The most frequent histological type was moderately differentiated adenocarcinoma. The follow-up of our patients is 43 months and 5 months, with an average of 47 months. The extent of tumor necrosis was less than 50% (73%) and more than 50% (27%). A total of 56% of patients with >50% necrosis also had vascular emboli. **Discussion:** Previously, tumor necrosis has shown

prognostic value in a variety of solid organ tumors including renal, breast, lung, pancreatic, and colorectal (Richards *et al.*, 2012; Gong *et al.*, 2021). It appears from these and similar studies that necrosis is not an isolated pathological feature but is strongly related to other aggressive features, including tumor size, grade and pathological stage (Richards *et al.*, 2012; Komori *et al.*, 2013). In our series, the presence of necrosis was associated with an advanced stage, weak differentiation and vascular invasion. The lack of a significant relationship between necrosis and survival may be explained by the limited numbers of patients in our sample. **Conclusion:** Our results show that tumor necrosis has a negative impact on patient prognosis and survival and should be included as a histoprognostic factor in Pathology reports.

Keywords: necrosis, carcinoma, colon; Morocco.

Competing interest and funding: We declare no conflict of interest.

References

- Keum, N. N. and Giovannucci, E. (2019). Global burden of colorectal cancer: emerging trends, risk factors and prevention strategies. *Nature Reviews Gastroenterology & Hepatology*, 16 (5).
- Pollheimer, M. J., Kornprat, P., Lindtner, R. A., Harbaum, L., Schlemmer, A., Rehak, P., and Langner, C. (2010). Tumor necrosis is a new promising prognostic factor in colorectal cancer. *Human Pathology*, 41(12), 1749-1757.
- Richards, C. H., Roxburgh, C. S. D., Anderson, J. H., McKee, R. F., Foulis, A. K., Horgan, P.G., & McMillan, D. C. (2012). Prognostic value of tumour necrosis and host inflammatory responses in colorectal cancer. *Journal of British Surgery*, 99(2), 287-294.
- Gong, K., Guo, G., Beckley, N., Zhang, Y., Yang, X., Sharma, M., and Habib, A. A. (2021). Tumor necrosis factor in lung cancer: Complex roles in biology and resistance to treatment. *Neoplasia*, 23(2), 189-196.
- Komori, K., Kanemitsu, Y., Kimura, K., Hattori, N., Sano, T., Ito, S., and Shimizu, Y. (2013). Tumor necrosis in patients with TNM stage IV colorectal cancer without residual disease (R0 Status) is associated with a poor prognosis. *Anticancer Research*, 33(3), 1099-1105.

This Supplement was published in partnership
with the
Moroccan Association of Pathology
& is part of
JMSR Pathology Collection



Copyright © 2012-2024 JMSR Pathology. This is an open access article published under Creative Commons Attribution -Non Commercial- No Derives 4.0 International Public License (CC BY-NC-ND). This license allows others to download the articles and share them with others as long as they credit you, but they can't change them in any way or use them commercially.