

COMPARISON OF ANALGESIC EFFICACY OF SERRATUS ANTERIOR PLANE BLOCK AND PECTORAL NERVE BLOCK IN PATIENTS UNDERGOING BREAST SURGERY

Namita Gupta¹, Gaurav goyal², Durga Jethava³, Pankhuri shrivastava⁴

¹Department of Palliative Medicine, Mahatma Gandhi Medical College, Jaipur, India.

²Department of Anesthesiology, Mahatma Gandhi Medical College Jaipur, India.

³Head of Department of Anesthesiology, Mahatma Gandhi medical college, India.

⁴Department of Anesthesiology, Apex hospital, Jaipur, Rajasthan, India

ABSTRACT

Objective: Breast surgery is usually associated with intense post-operative pain, which lead to chronic pain. We compared the analgesic efficacy of two ultrasound guided nerve blocks that is Pectoral nerve block (PECS) and Serratus anterior plane block (SAP) post operatively. **Material and Methods:** This double-blind, randomized study was conducted on 60 adult females, who were posted for breast surgery. General anesthesia was given with intravenous midazolam 1 mg, fentanyl 1 mcg/kg for premedication and then injection propofol 1–2 mg/kg and vecuronium 0.1 mg/kg. After this all patients received either ultrasound guided PECS block at 3-4th rib Group 1 (n = 30) or SAP at 5th rib Group 2 (n = 30) with 0.375 % bupivacaine with dexmedetomidine as adjuvant. Time when need of first rescue analgesia and tramadol consumption in 0, 2, 4, 6, 8, 12, 24 and 48h was noted. For pain assessment Visual analogue scale (VAS) scores and any adverse effect were recorded. **Results:** The mean duration of analgesia (mean ± Standard deviation [S.D.]) observed longer in the PECS group as compared to SAP group 21.6 hours v/s 23 hours (1380 ± 382 min v/s 1296 ± 232 min). The post-operative analgesic consumption was significantly higher in the SAP group (200mg) as compared to PECS group (133.3 mg) (p-value < 0.001). **Conclusion:** Ultrasound guided SAP block is a good analgesic alternative for breast surgery, although PECS block has a better analgesic profile than SAP block.

Key Words: Breast surgery, Nerve block, Pectoral nerve block, Postoperative analgesia, Serratus anterior plane block

Corresponding Author:

Namita Gupta, MD.

Affiliation: Department of Palliative Medicine, Mahatma Gandhi Medical College, Jaipur, India.

E-mail: drnamita2007@gmail.com

Copyright © 2012- 2020 N. Gupta. This is an open access article published under **Creative Commons Attribution -Non Commercial- No Derives 4.0 International Public License (CC BY-NC-ND)**. This license allows others to download the articles and share them with others as long as they credit you, but they can't change them in any way or use them commercially.

*****Published in Marsh 10, 2022.

doi: 10.46327/msrjg.1.000000000000214

doi url: <https://doi.org/10.46327/msrjg.1.000000000000214>

INTRODUCTION

Ultrasound-guided muscular plane blocks, now have changed the practice of anesthesia for breast surgeries. Thoracic plane blocks represent a novel and rapidly expanding facet of regional anesthesia. Regional blocks have led to a decreased need for analgesics, maintenance of hemodynamic stability, early ambulation and discharge of patients and lower hospital cost. [1, 2]

The innervations of breast is by anterior and lateral cutaneous branches of the thoracic intercostal nerves (T2 to T6) and also by Supraclavicular nerves.

Supraclavicular nerves originate from the lower fibers of the cervical plexus and play their role in innervations of the upper and lateral portions of the breast while cutaneous branches of intercostal nerves supply the parasternal region of breast.[1,3] The mechanism of action of Serratus anterior plane block (SAP) is blockade of the lateral cutaneous branches of the intercostal nerves (T2–T4 for SAP), which is very much similar to the other plane block Transversus abdominis plane (TAP) block.[3]

These newly described analgesic techniques offer the potential for very good analgesia, enhanced technical

safety profiles, and reduced physiological side effects versus traditional techniques in thoracic-anesthesia.³ The SAP block was given in the interfascial plane of the Serratus anterior muscle at T5. [1, 4]

Thoracic paravertebral block (TPVB) unable to anesthetize medial and lateral pectoral nerves and also long thoracic and thoraco-dorsal nerves. [5] TPVB is less preferable for breast surgeries which involve axillary dissection. Serratus anterior plane (SAP) block performed with ultrasound guided technique provides complete anesthesia and analgesia to the lateral thoracic wall. Its use has been documented in literature with good analgesia in breast reconstruction surgeries. [6]

Pectoral nerve block (PECS) and SAP blocks have some advantages, including no risk of sympathectomy that is usually associated with TPVB and epidural blockade. Added to this, these blocks have less restriction on the use of anticoagulants, as compared to TPVB or neuraxial blocks. The PECS are described into 2 types: PECS I and PECS II. PECS I is an easy and effective technique for superficial block that blocks the lateral and medial pectoral nerves at a plane between the Pectoralis major and Pectoralis minor muscles.[7] While it has good analgesia for varied surgeries on breast, it is prominently used for the breast expanders and sub pectoral prosthesis insertion. Many other indications include traumatic chest injuries, iatrogenic pectoral muscle dissections, pacemakers and chest drains.[8] PECS II target the long thoracic nerve, thoracic intercostal nerves from T2–T6, and thoracodorsal nerve.[9] All those strategies provide the patient with substantial analgesia through minimizing both intra-operative and postoperative opioid usage while retaining pulmonary function.

In this study, we compared PECS block with SAP block for analgesic efficacy for patients posted for breast surgery using 0.375 % Bupivacaine with adjuvant Dexmedetomidin.

AIMS AND OBJECTIVES

To compare the need of first rescue analgesia (in time) and total analgesic dose required in Pectoral nerve block to Serratus anterior plane block and to compare the efficacy of both blocks in terms of intraoperative hemodynamic stability and Visual Analogue Score(VAS) at rest and at movement at 2, 4, 6, 12, 20, 24 and 48 hours.

MATERIAL AND METHODS

This double-blind, randomized, prospective comparative study had been conducted, after getting approval from the Hospital's Ethics Committee

(MGUMST/MD/MS/2017/22-78-80) and written informed consent from sixty adult females, who were scheduled for elective Breast Surgery from January 2019 to July 2020.

Patients with American society of anesthesiologist (ASA) grade I/II and aged between 18 to 65 years were included in this study. Patients having coagulopathy, local infection at the site of block, allergy to anaesthetics drugs and significant co morbid conditions were excluded from this study.

Selected patients were randomized into two groups of 30 participants each using computer-generated randomization in sealed envelope technique with triple-blinding (patient as well as block operator and an independent investigator who assesses analgesia in post-operative period:

Group 1 SAP: Patients receiving Serratus anterior plane block group.

Group 2 PECS: Patients receiving Pectoral nerve block group.

At the time of pre-anesthetics checkups (PAC), patients were educated about the VAS score system and consent for blocks was taken. After a period of 8 hours Nil per oral (NPO) duration and evaluation of the patient's airway, difficulty in intubation been ruled out and patient was taken to the surgery where, after checking the name and site of the procedure, the 18-gauge wide bore intravenous (IV) cannula was taken and standard ASA monitors were attached. Patients were pre-medicated with Midazolam 1 milligram (mg), Fentanyl 1 microgram (mcg/ kg) to prevent the stress response of laryngoscopy and intubation. All the patients were pre-oxygenated for three minutes and intravenous (IV) injection of glycopyrrolate 0.2 milligram (mg) was administered. Induction of anesthesia was done with IV Propofol 1% 1–2 mg/ kg (milligram/kilogram). Intubation was performed after administration of Vecuronium Bromide 0.1 mg/kg intravenously and patients were ventilated to achieve an adequate value of End-tidal carbon dioxide.

In Group 1: Serratus anterior plane block was given intra-operatively with the patient lying supine, the ultrasound probe was placed at mid clavicle. After identifying the second rib, the probe was moved distally and obliquely, towards the mid- axillary line to identify the 3rd to 5th ribs. The final probe position is obliquely over the axillary line, now serratus anterior muscle and latissimus dorsi muscles were identified in the mid-axillary area. Using ultrasound, a 22 gauge, 50 mm echogenic needle was advanced under all aseptic precautions in plane method to enter this myofascial plane. Confirming the right probe position under Ultrasound (USG) guidance, after hydrodissection with saline, 0.4ml/kg of 0.375 % bupivacaine and

dexmedetomidine 1mcg/kg body weight was injected just above the Serratus anterior muscle. (**Figure 2**)

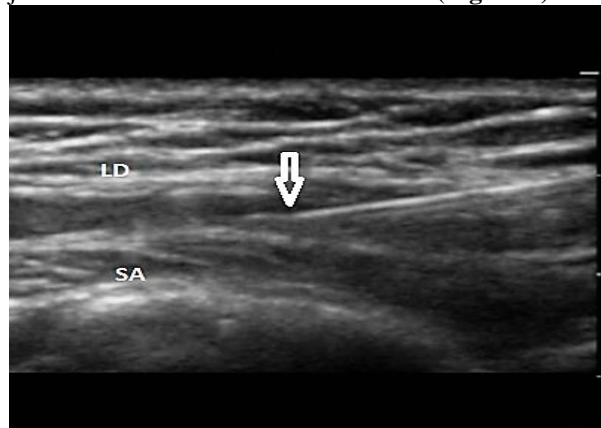


Figure 2: Serratus Anterior Plane Block (SAP); LD- Latissimus Dorsi muscle; SA- Serratus Anterior muscle; Arrow (↓) Showing Needle entry

Group 2: Pectoral nerve block (PECS I and II) was performed after intubation. Patient lying supine and their ipsilateral upper limb kept in the abducted position. Experienced anesthesiologist who performed the blocks were standing on the side to be blocked and sonosite was placed on opposite side, After skin sterilization using 2 % betadine solution a linear high frequency ultrasound probe was placed at infraclavicular region and probe moved inferolaterally to identify Pectoralis major, Pectoralis minor and the thoracoacromial vessels between the pectoral muscles. Then a 22 gauge, 50 mm echogenic needle was inserted in plane to probe in fascial plane between pectoralis minor muscle and serratus anterior muscle. After hydrodissection with 2-3 ml of 0.9 % saline, 0.2ml/kg of Bupivacaine 0.375 % with Dexmedetomidine 0.5 mcg/kg was injected. Then the needle was withdrawn and redirected into the fascial plane between Pectoralis major and minor muscles, again after hydro dissection with 0.9 % saline, 0.2ml/kg of 0.375 % bupivacaine with dexmedetomidine 0.5mcg/kg was injected. Thus all patients of either group receive same amount of local anaesthetics and adjuvant drug dose (**Fig. 3**).

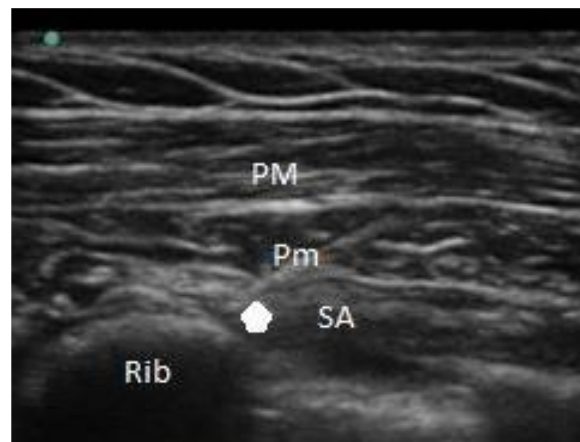


Figure 3: Pectoral Nerve block (PEC); PM- Pectoralis major muscle; Pm- Pectoralis minor muscle; SA –Serratus anterior muscle; Arrow (↑) Showing Needle entry.

Major vital signs including heart rate, pulse oximeter saturation, systolic blood pressure, diastolic and mean blood pressure were recorded before anesthesia, after induction, 5 min. after induction and then every 10 min, until the surgery ends.

Postoperatively all patients were assessed at 2, 4, 6, 8, 12, 24 and up to 48 hours for pain using Visual Analogue Score at rest and at the movement. Patients having pain at any instance of time post operatively were given injection Tramadol 100mg intravenously in 100ml saline slowly as rescue analgesic. Intravenous ondansetron (4mg) was administered prior to giving Tramadol. Intravenous paracetamol 1000 mg was given to all patients each 12 hours as an analgesic agent independently of pain score in the following 24 hours as per hospital protocol.

Statistical Analysis

Statistical analysis was done using SPSS 20 software. Categorical data were compared using Chi square test. The quantitative data were compared by student t-test.

RESULTS

The total number of patients enrolled for this study was 60 in two groups with 30 in group 1 (SAP) and 30 in group 2 (PECS); demographic data were comparable. (**Table 1**)

Table 1. Demographic data age and weight is represented as percentage and weight is represented as mean and S.D.

	SAP	PECS
Age 18-40 years	33.3 %	26.6 %
41-65 years	66.6 %	73.3 %
Mean ± S.D.	44.73 ±13.76	47.03±12.33
Weight (kg) (Mean± S.D.)	58.8 ±9.3	58.5±9.4
ASA I	86.6 %	83.3 %
ASAI	13.3 %	16.6 %

S.D.-standard deviation

There was a significant difference (P -value<0.001) between the dose of analgesic requirement between the SAP and PECS block group, the mean value of dose of analgesic was 200 mg in SAP group and 133.33 mg in PECS group. (Table 2)

Table 2. Comparison of mean dose of analgesic between the groups

	SAP		PECS	
	Mean	S.D.	Mean	S.D.
Mean Analgesic dose (mg)	200.00	122.47	133.33	57.73
Range	100mg-400mg		100mg-200mg	
Result (p -value)	P -value<0.001 (S)			

S.D: standard deviation, mg - Milligram

There was significant difference in VAS Score at movement in post-operative period in both the groups at 6 hours and 8 hours with P -value of 0.006 and 0.027 respectively. Also VAS score at movement was always less in PECS group than SAP group. (Table 3)

Table 3: Comparison of pulse rate between groups

Pulse rate (bpm)	PECS		SAP		Result (p -value)
	Mean	S.D.	Mean	S.D.	
At 0 min	83.53	7.54	88.93	6.29	0.003 (S)
Induction	86.20	8.34	89.53	7.51	0.109 (NS)
5 min	78.77	7.59	83.73	8.29	0.018 (S)
10 min	74.60	5.29	77.97	6.33	0.029 (S)
30 min	70.20	5.58	76.24	7.99	0.001 (S)
1 hour	70.21	9.29	77.93	7.17	0.0007 (S)

S-significant, NS-non significant, min-Time in minutes

When we compare the systolic blood pressure in both groups, there was a decrease in mean value of systolic blood pressure in PECS group as compared to SAP group at 5 min and 10 minutes and this difference is statistically significant, with P -value of 0.023 and 0.015 respectively. Systolic blood pressure remains decreased in PECS group during whole of the surgery (Fig. 1)

Table 3. Table showing comparison of Visual Analogue Scale (VAS) at movement

t	SAP		PECS		Result (P - value)
	Mean	S.D.	Mean	S.D.	
0 Hr.	0.63	1.00	1.13	0.35	0.012 (S)
2 Hr.	1.17	0.91	1.23	1.28	0.816 (NS)
4 Hr.	0.63	0.61	1.00	1.17	0.135 (NS)
6 Hr.	0.63	0.61	0.97	0.18	0.006 (S)
8 Hr.	1.13	1.20	0.60	0.50	0.027 (S)
12 Hr.	1.00	0.95	0.93	0.45	0.728 (NS)
24 Hr.	1.10	1.56	1.13	0.94	0.920 (NS)
48 Hr.	1.30	1.34	1.43	1.57	0.724 (NS)

Significant (S), Non-significant (NS), Hr: Time in hour; t: time

The mean time for rescue analgesia was 21.6 hours in case of SAP block and 23 hours for PECS block. The P -value was 0.44 which is statistically non-significant (Table 4)

Table 4: Comparison of Mean time of rescue analgesia

	Mean	S.D.
SAP	21.6 hr (1296min)	3.88 (232.8min)
PECS	23 hr (1380 min)	6.37 (382.2)

P -value = 0.44 (N.S) Nonsignificant

There was statistically significant difference seen in pulse rate between both the blocks at time 0 min, 5 min after induction and 10 min, 30 min and 1 hour with P -value being 0.003, 0.109, 0.018, 0.029, 0.001 and 0.0007 respectively. There was lesser value of pulse rate seen in PECS block group. (Table 5)

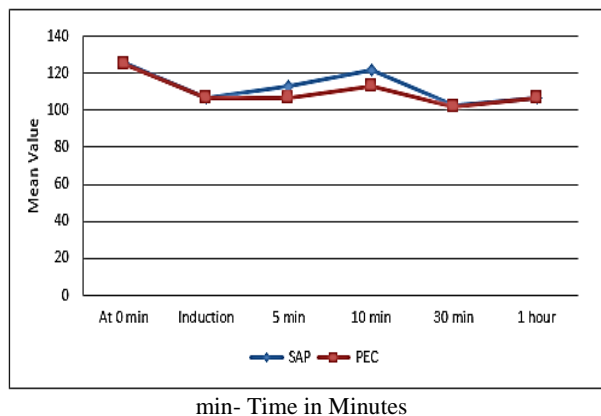


Figure 1: Graph showing comparison of systolic B.P between the groups

DISCUSSION

This is one of the few studies to compare analgesia potential and hemodynamic stability of PECS blocks and SAP for managing of postoperative pain after breast surgeries. This study demonstrated that both PECS and SAP blocks were associated with hemodynamic stability and good post-operative analgesia. PECS block has been associated with superior analgesic profile when given along with general anesthesia in patients who underwent breast surgery. It is associated with lower intra operative and post-operative opioid consumption and low VAS score in post-operative period. Kapil Gupta et al [5] found post-operative patient controlled morphine consumption as analgesic was low in PVB group ($8.8\text{mg}\pm 2.3$) as compared to SAP group in which morphine consumption was ($12.0\text{mg}\pm 2.4$) in 48 hours. Basak et al [13] conducted comparative study of modified pectoral nerve block versus Erector spinae block (ESP) on post-operative opioid consumption and pain score of patients after radical mastectomy and concluded that mean tramadol consumption in PECS group was low as 132.78 ± 22.44 mg whereas in Erector spinae group (ESP) it was $196\pm 27.03\text{mg}$.

Kulhari et al. [10] presented a comparative study of PECS II block to thoracic paravertebral block during radical mastectomy. They also found 24 hours morphine consumption was also less (3.9 ± 0.79 mg) in PECS group as compared to (5.3 ± 0.98 mg) in TVPB group. Bashandy and Abbas [9] in 2016 conducted randomized study with 2 groups: one with general anesthesia (GA) alone and another with GA associated to PEC block and found that the PECS group had less post-operative analgesic requirement. A study by Wang K et al [17] concluded that PECS block when combined with SAP block gives good peri-operative relief from pain following modified radical mastectomy; there was low post-operative morphine consumption (3.67mg) and intra-operative fentanyl consumption in PECS block.

These studies correlate with our study. We found a significant difference ($P\text{-value}<0.001$) between the

dose of analgesic requirement between the SAP and PECS block groups, SAP group with mean dose being 200mg compared to PECS group in which the mean analgesic requirement was 133.3mg. (Tables 1 and 2) Perez Herrero et al [16] compared postoperative recovery following breast surgery in randomized controlled study where 60 patients received either GA along with Paravertebral block or Serratus-intercostal block and concluded there was no significant difference in quality of post anesthesia recovery as quantified by Post-operative Quality Recovery Scale at different times (15 minutes after the end of surgery, at discharge to home and 1 month after surgery).

In a comparative study between ESP and PECS block conducted by Basak et al. [13], numerical rating scale (NRS) scores at the 15th and 30th min were similar between the groups; median NRS scores were significantly less in PECS group at postoperative 60th min, 120th min, 12th hour and 24th hour with respectively $P\text{-value} = 0.024$, $P\text{-value} = 0.018$, $P\text{-value} = 0.021$ and $P\text{-value} = 0.011$. Syal and Chandel [11] found that VAS score was lower in PVB group compared to PEC group at 0, 2, 4, 12 and 24 hours being 3, 4, 3, 3 for PVB and 3, 4, 4, 4 for PEC groups. Zhao et al. [14] studied pectoral nerve block for modified radical mastectomy in meta-analysis based on randomized controlled trials and found that the number of patients requiring postoperative rescue analgesia in the PECS I and PECS II groups was significantly lower compared to control group. Doo-Hwan kim [15] et al (2018) found that the numerical rating scale (NRS) was consistently lower through 24 hours in the PECS II group and concluded that the PECS II block seemed to reduce pain intensity and opioid requirements for 24h. Bashandy and Abbas [9] (Repetition removed) observed significantly lower VAS score in block with GA group than GA alone group. In our study, there was significant difference in VAS Score at movement in post-operative period in both groups at 6 hours and 8 hours. VAS score at movement was always less in PECS group compared to SAP group. (Table 3). Rahimzadeh et al [6] stated that Serratus block efficiently decreases postoperative use of opioid and prolonged analgesia after mastectomy. But it did not attenuated VAS scores when comparison with the control group was done.

This dichotomy with our study may be due to the fact that they performed the block postoperatively; in our study it was performed before surgery starts. Moreover it was noted in their study that the control group consumed fentanyl by patient control analgesia (PCA) more in postoperative period than the Serratus group, which might affect the pain scores.

Kulhari et al [10] found PECS block superior to paravertebral block (PVB). The analgesia duration was prolonged significantly in PECS group ($294\pm 52.76\text{min}$) as compared to TVPB group ($197.5\pm 31\text{min}$). In the study conducted by Syal and Chandel [11], the mean

duration of analgesia was (639.0 ± 79.6 min) in PVB as compared to PEC group (466.5 ± 37.0 min) and Local anesthetic group (268.5 ± 35.7 min).

Mary Thomas et al [12] gave pectoral nerve block for surgery for breast cancer; time to first request of analgesia was 353.93 ± 135.03 min after pectoral nerve block. This study supports our findings; we also found that the time to first rescue analgesia was prolonged in PECS block (23 hours) as compared to SAP block (21.6 hours). The use of dexmedetomidine as an adjuvant to bupivacaine prolonged the duration of the analgesic effect. (**Table 4**). In our study, the mean value of systolic blood pressure decreased in PECS group as compared to SAP group at 5 min and 10 minutes and the difference was statistically significant with p-value of respectively 0.023 and 0.015. Systolic blood pressure remains decreased in PECS group during entire course of the surgery. (Figure: 1). However, there were statistically significant differences seen in pulse between both blocks at time 0 min, 5 min after induction and 10min, 30min and 1 hour with P-value being 0.003, 0.109, 0.018, 0.029, 0.001 and 0.0007 respectively. There was lesser value of pulse rate in PECS group as compare to SAP group. (**Table 5**). Bashandy and Abbas [9] concluded in their study that PECS groups showed less significant changes in hemodynamic as compared to other groups and therefore low intraoperative fentanyl consumption.

Gupta et al [5] conducted a study with ultrasound guided PVB versus Serratus anterior plane block; they suggest that intra-operatively the systolic blood pressure and heart rate remained stable in both blocks and their values were comparable in both groups. Local anesthetic is injected between the Pectoralis major and Pectoralis minor muscle, for PECS I block which blocks the medial pectoral nerve and lateral pectoral nerve and then between pectoralis minor and serratus anterior muscle for PECS II block which will block anterior cutaneous branches of intercostal nerves 3 to 6, the intercosto-brachial nerves, and the long thoracic nerve, thereby giving complete analgesia of chest wall. Addition of dexmedetomidine, adequate volume and probably better technique were the reasons why we found longer duration, less rescue analgesia requirement and comparable hemodynamic stability in PECS group as compared to other blocks.

Blanco et al. [4] proposed SAP block as an alternative to PVB for surgeries on anterior and lateral chest wall. They said that performing SAP block was easy as Serratus anterior muscle is good landmarks which can be find easily. In SAP block, injection of drugs at the 5th rib primarily blocks long thoracic nerves and thoracic intercostal nerves, providing complete analgesia to much of the chest wall, impacting both the anterior and the lateral cutaneous branches. SAP block is a relatively recent compartment block identified in anesthesia literature for the treatment of thoracic wall pain. This

innovative regional anesthetic technique can also be ideal for peri-operative analgesia for a variety of surgical procedures, including surgery requiring incisions on the antero-lateral chest wall, such as insertion of chest drainage, reconstructive breast surgery and cosmetic breast surgery. [4]

PECS block is considered as peripheral nerve block that was recently described as safe and effective procedure. Anesthesiologists recently advocate PECS block to TPVB and thoracic epidural analgesia. Advantages of the PECS block include absolutely no risk of sympathectomy that is a usual association of thoracic paravertebral block and neuraxial block. Added to this, the PEC block has less restriction on anticoagulants use, as compared to TPVB or thoracic epidural block.

Though the PEC block has risk of injection in the intravascular space, the use of real time ultrasound reduces the chances of injection of local anesthetic agent in the thoraco- acromial artery. We can avoid these complications with proper training and confirming the right spread of the local anesthetics under ultrasound. Most of the times, the breast surgeries are performed on the outpatient basis; therefore, this block may be a good anesthetic technique with safety, reducing the hospital stay and less economic burden. The results of our study would surely add to the scarce amount of data available, regarding the analgesic ability of PECS and SAP blocks in breast surgeries and thereby support the place of these blocks as an addition to already existing techniques for multimodal analgesia in breast cancer surgery.

CONCLUSION

We can therefore conclude in this study that both PECS and SAP block are effective in providing good amount of analgesia in post-operative period and intraoperative hemodynamic stability in patients undergoing breast surgeries. However Pectoral nerve block has better analgesic profile than SAP block in such cases.

ACKNOWLEDGEMENTS

The author thanks to all patients for their contribution and to all attending faculty of department.

FUNDING SOURCE: None

CONFLICT OF INTEREST:

The authors report no conflict of interest.

REFERENCES

1. Richman JM, Liu SS, Courpas G, Wong R, Rowlingson AJ, McGready et al . Does continuous peripheral nerve block provide superior pain control to opioids? A meta-analysis. *Anesth Analg* 2006; 102: 248-57.
2. Chakraborty A, Khemka R, Datta T. Ultrasound-guided truncal blocks: A new frontier in regional Anaesthesia .*Indian J Anaesth* 2016; 60: 703-11.
3. Garg R, Bhan S, Vig S. Newer regional analgesia interventions (fascial plane blocks) for breast surgeries: Review of literature.*Indian J Anaesth* 2018; 62: 254-62.
4. Blanco R, Parras T, McDonnell JG, Prats-Galino A. Serratus plane block: a novel ultrasound-guided thoracic wall nerve block. *Anaesth* 2013; 68:1107-13.
5. Gupta K, Srikanth K, Girdhar KK, Chan V. Analgesic efficacy of ultrasound-guided paravertebral block versus serratus plane block for modified radical mastectomy: A randomised, controlled trial. *Indian J Anaesth* 2017; 61: 381-6.
6. Rahimzadeh P, Imani F, Faiz SH, Boroujeni BV. Impact of the ultrasound-guided serratus anterior plane block on post-mastectomy pain: a randomised clinical study. *Turk J Anaesthesiol Reanim* 2018; 46: 388-92.
7. De Cassai A, Bonanno C, Sandei L, Finozzi F, Carron M, Marchet A. PECS II block is associated with lower incidence of chronic pain after breast surgery. *Korean J Pain* 2019; 32: 286-91.
8. Kamiya Y, Hasegawa M, Yoshida T, Takamatsu M, Koyama Y. Impact of pectoral nerve block on postoperative pain and quality of recovery in patients undergoing breast cancer surgery. *Eur J Anaesthesiol*. 2018; 35: 215-23.
9. Bashandy GM, Abbas DN. Pectoral nerves I and II blocks in multimodal Analgfor breast cancer surgery: a randomized clinical trial. *Reg Anesth Pain Med* 2015; 40: 68-74.
10. Kulhari S, Bharti N, Bala I, Arora S, Singh G. Efficacy of pectoral nerve block versus thoracic paravertebral block for postoperative Analgafter radical mastectomy: a randomized controlled trial. : *Br. J. Anaesth*.2016; 117: 382-6.
11. Syal K, Chandel A. Comparison of the post-operative analgesic effect of paravertebral block, pectoral nerve block and local infiltration in patients undergoing modified radical mastectomy: a randomised double-blind trial. *Indian J Anaesth* 2017; 61: 643-8.
12. Thomas M, Philip FA, Mathew AP, Krishna KJ. Intraoperative pectoral nerve block (Pec) for breast cancer surgery: a randomized controlled trial. *J Anaesthesiol Clin Pharmacol*. 2018; 34: 318-23.
13. Altıparmak B, Toker MK, Uysal Aİ, Turan M, Demirbilek SG. Comparison of the effects of modified pectoral nerve block and erector spinae plane block on postoperative opioid consumption and pain scores of patients after radical mastectomy surgery: a prospective, randomized, controlled trial. *J Clin Anesth*. 2019; 54: 61-5.
14. Zhao J, Han F, Yang Y, Li H, Li Z. Pectoral nerve block in anesthesia for modified radical mastectomy: A meta-analysis based on randomized controlled trials. *Medicine (Baltimore)*. 2019; 98(18):e15423. 1-8
15. Kim DH, Kim S, Kim CS, Lee S, Lee IG, Kim HJ et al. Efficacy of pectoral nerve block type II for breast-conserving surgery and sentinel lymph node biopsy: a prospective randomized controlled study. *Pain Res Manag* 2018; Article ID 4315931:1-8.
16. Pérez Herrero MA, López Álvarez S, Fadrique Fuentes A, Manzano Lorefice F, Bartolomé Bartolomé C. Quality of postoperative recovery after breast surgery. General anaesthesia combined with paravertebral versus serratus-intercostal block. *Rev Esp Anesthesiol Reanim*. 2016 Dec; 63 (10): 564-571.
17. Wang K., Zhang X., Zhang T., et al. The efficacy of ultrasound-guided type ii pectoral nerve blocks in perioperative pain management for immediate reconstruction after modified radical mastectomy: a prospective, randomized study. 2018; 34: 231–236.