

## PRIMARY AND BILATERAL NON HODGKININ'S LYMPHOMA OF THE ADRENAL GLAND: -ABOUT TWO CASES REPORT-

Ratbi El Amine, Jahid Ahmed\*, Younes Cherradi\*\*, Belkouchi Abdelkader

Surgical Clinic A, Ibn Sina University Hospital, Rabat, Morocco.

\*Pathology department, Ibn Sina University Hospital. – Rabat, Morocco.

\*\*Department of Medicine, Mohammed V<sup>th</sup> Hospital, Sefrou, Morocco.

### ABSTRACT

Primary adrenal lymphoma is a very rare condition; it represents less than 0.5% of all adrenal tumors. Adrenal lymphoma is often bilateral and is mostly a B-cell type. T-cell lymphoma is exceptional. Diagnosis and treatment are challenging and prognosis is pejorative. We are reporting the case reports of two patients with primary and bilateral adrenal lymphoma. Both patients were operated without histological evidence, for the first, adrenalectomy with right nephrectomy and biopsy of the left mass were performed, histological result show the non-Hodgkin's lymphoma cell-T, the evolution were marked with the death of patient by pulmonary embolism after the first cycles of chemotherapy, for the second patient left adrenalectomy and biopsy of the right mas were made, the histological study showed the non-Hodgkin's lymphoma cell-B, the deceased patient in the outcomes. A review of literature displays the pejorative prognosis of these tumors. The objective is to have a less aggressive etiological approach without exploratory surgery.

**Keywords:** Adrenal; Bilateral; Lymphoma; Primary.

### Corresponding Author:

Ratbi El Amine, MD.

**Address:** Surgical Clinic A, Ibn Sina hospital- Rabat, Morocco.

**E-mail:** [eratbi14@gmail.com](mailto:eratbi14@gmail.com)

**Tel:** + (212) 661899778

**Copyright © 2012- 2020 Dr. Ratbi El Amine and al.** This is an open access article published under **Creative Commons Attribution -Non Commercial- No Derives 4.0 International Public License (CC BY-NC-ND)**. This license allows others to download the articles and share them with others as long as they credit you, but they can't change them in any way or use them commercially.

\*\*\*\*\*Published in June 30, 2020.

doi: 10.46327/msrjg.1.000000000000xxx

doi url: <https://doi.org/10.46327/msrjg.1.000000000000xxx>

### INTRODUCTION

Primary adrenal lymphoma (PAL) is very rare, accounting for approximately 0.5% of all adrenal malignancies. About 200 cases have been reported to date. The bilateral presentation is frequent and large B- cell type is prominent in histology. Diagnosis and management are real issues and prognosis remains always pejorative. We report 2 cases of primary and bilateral non-Hodgkin's lymphoma of adrenal.

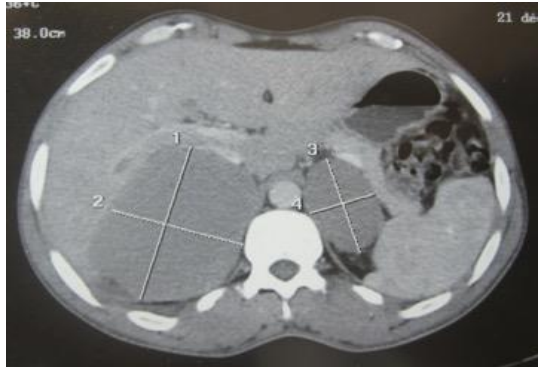
### CASE REPORTS

#### Case I:

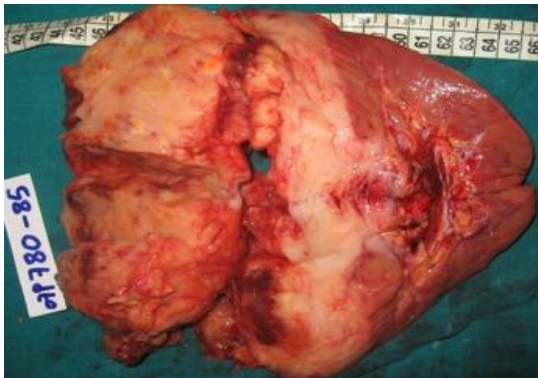A 43-year-old patient with no medical history, presented brutally an acute abdominal pain in the

right flank with sweat, headache and fever. Clinical examination found sensitivity in the right flank. Abdominal CT scan revealed a rounded mass of the right adrenal gland pushing the right kidney and liver with contact with the inferior vena cava associated with another mass of the left adrenal gland, there was without hepatic metastases (Figure 1). Cortisolemia and methoxylated derivatives were normal. A bone marrow biopsy specimen was performed to rule out secondary lymphoma; the result was negative. Median laparotomy revealed a huge right adrenal mass with invasion of the right kidney and all the retroperitoneal space. One-piece right adrenalectomy with right nephrectomy were performed. Biopsy was taken from left mass biopsy (Figure 2). The histological study with immunohistochemistry confirmed the diagnosis of primary non-Hodgkin's malignant lymphoma with

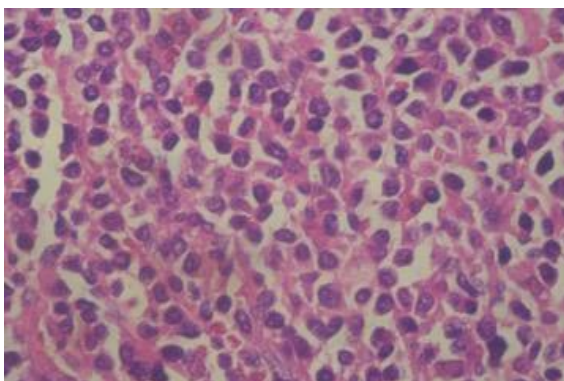
large T-cells phenotype (Figure 3). Chemotherapy was indicated. Patient died after pulmonary emboli following first chemotherapy.



**Figure 1:** Abdominal CT showing the two right adrenal masses pushing back the liver and right kidney and in contact with the inferior vena cava and left adrenal mass.



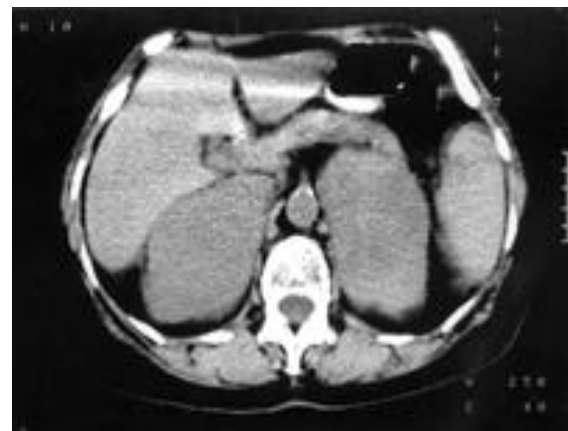**Figure 2:** Adrenal and right kidney tumorectomy



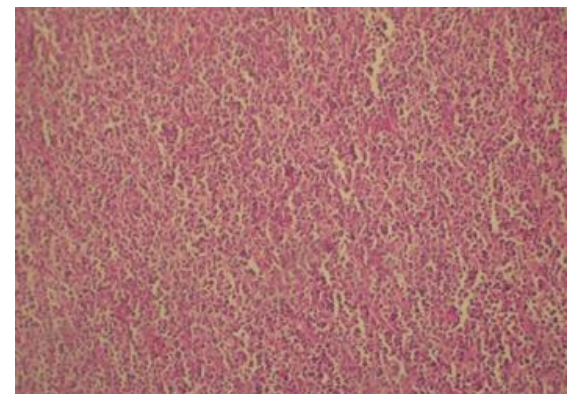
**Figure 3 :** Histological aspect of non-Hodgkin malignant large T-cell lymphoma (G x 20)

**Case II:** A 54 year-old patient with no medical history, was complaining from localized abdominal pain in both flanks during the last 04 months associated with vomiting, fever and important weight loss. Clinical examination found an altered patient with tachycardia at 110 and localized tenderness to both sides without lumbar contact and palpable mass on palpation. The abdominal ultrasound and CT scan showed two adrenal mass

weakly enhanced after contrast injection (Figure 4): the right mass pushing back the IVC with invasion of the upper pole of the right kidney. There was no liver metastases or deep lymphadenopathy. Biologically the patient had hypokalemia with minimal elevation of normetanephrin. Median laparotomy showed the presence of two large adrenal masses. A left adrenalectomy with a biopsy of the right adrenal mass were performed. The histological study with immunohistochemistry revealed non-Hodgkin's malignant lymphoma large phenotype B-cells (Figure 5). The patient died in the post-operating suites.



**Figure 4:** Abdominal CT showing the 2 hypodense adrenal lesions weakly enhanced after the PC measuring right 11x6cm and left 10x5cm. The right mass pushes the inferior vena cava and invades the upper pole of the kidney.



**Figure 5:** Histological aspect showing non-Hodgkin's large cell malignant lymphoma of B-cell phenotype

## DISCUSSION

Anusual locations and special presentations of lymphoma has been reported in literature (biliary tract, conjonctiva, and others....) and interest in this entity is particular (1- 3). Isolated Primary lymphomas of adrenal gland are exceptional, representing less than 0.5% of all adrenal neoplasm. Secondary forms due to lymphomatous infiltration

are mostly reported (4, 5). Isolated Primary lymphomas of adrenal gland are prominent in men (sex ratio= 3/1) and mean of age is 39-89 year-old (7, 8). Bilateral involvement is most common and adrenal function often remains normal, the diagnosis is based on histology and immunohistochemistry findings (8, 8).

Etiopathogeny is still unexplained but the role of Epstein Barr Virus has been suggested (9). The most common mode of presentation is either related to lymphoma itself with fever, altered general condition, abdominal pain and weight loss. Symptoms could be related to adrenal insufficiency (4, 10, 11), but usually the diagnosis is late and accidental (12); Maugendre reported 14 cases (13). Asymptomatic cases with post-operative diagnosis are exceptional (14, 15). Biology is not specific, it may show inflammatory biological syndrome, elevated LDH rates or hypercalcemia (16, 17). Diagnosis can be suspected on imaging findings. Abdominal ultrasound of adrenal masses can be echoic with liquid zones corresponding to hemorrhagic or necrotic areas (4,18-20). The adrenal CT scan usually shows a well-limited oval homogeneous mass that is slightly enhanced by the contrast agent (21). Arguments supporting the diagnosis of lymphoma are: the large size > 3cm and the absence of fatty area or calcification or hypervascular character (22) but those are not specific criteria. The MRI allows the visualization of adrenal masses but does not make the difference between lymphoma and metastasis (17, 22). The definitive diagnosis is histological specimen (18-20); Biopsy specimen could be performed by ultrasound or CT scan guidance. Laparotomy must be suggested as a last option and after eliminating a pheochromocytoma. However, Luton proposes systematic surgery (23). In our cases, laparotomy was performed first with the intention of an adrenalectomy but due to the local invasion, only a simple biopsy was done.

Primary adrenal lymphoma may be confused with undifferentiated carcinoma or metastatic lesions of the adrenal gland. Immunohistochemical study should be performed with lymphoid markers before definitive diagnosis is made (24). Large cell lymphoma (high grade according to Kiel) is clearly prominent (71% vs 11% small cell lymphoma). Phenotype B is the predominant according to the review of Lecaltier et al (18, 19). For our patients, T-cell and B-cell phenotypes were found. To retain the primitive character of lymphoma, it is necessary to confirm the absence of other localization. Clinical examination is important, checking the absence of nodes, hepatomegaly and splenomegaly. Bone marrow biopsy is indicated. Thoraco-abdominal CT-scan, upper gastrointestinal endoscopy, colonoscopy

and bronchoscopy should be all performed with multiple biopsies and a (4). In our patients, all investigation showed negative results which confirmed the primary adrenal location of non-Hodgkin's lymphoma. Regarding the severity of the disease, poly-chemotherapy based on CHOP or MACOP-B seems to be the treatment of choice (4, 18, 19). Surgery alone or in combination with chemotherapy or adjuvant radiotherapy presents limited benefit (4). The prognosis of primary adrenal lymphoma is still considered fatal (4). Al-Fiar et al reported survival rate of 10 days to 11 months after diagnosis (25) which is significantly shorter than thyroid lymphomas (10). The literature reported rare cases with excellent response to treatment with prolonged total or partial remission (18). Prognosis factors are: age over 60 years old, tumor size greater than 10 cm, histological aggression and phenotype, existence of more than one extra-lymph node localization, high levels of LDH and  $\beta$ -2 macroglobulin up to 3 mg/l (18).

## CONCLUSION

Bilateral primary adrenal malignant lymphoma is a rare entity with bad prognosis. It must be evocated before any bilateral mass of the 2 adrenals, the diagnosis is histological. Mini-invasive approach is recommended for biopsy.

## CONFLICT OF INTEREST

There is no Conflict of Interest to declare.

## REFERENCES

1. H. Dahmane et al. Biliary Lymphoma Mimicking Cholangiocarcinoma: Case Report. Journal of Medical and Surgical Research –JMSR- 2017; IV, 1: 370- 372
2. N A. Drideb et al. Bilateral MALT (Mucosal Associated Lymphoid Tissue) Lymphoma of the Conjunctiva. A Rare Case Report. Journal of Medical and Surgical Research –JMSR- 2014; I (1): 22-23.
3. Y. Cherradi. Anusual Presentation of High Grade Lymphoma. Journal of Medical and Surgical Research –JMSR- 2018; V (1): 506.
4. Pimentel M, Johnston JB, Allan DR, Greenberg H, Bernstein CN. Primary adrenal lymphoma associated with adrenal insufficiency: a distinct clinical entity. *Leuk Lymphoma* 1997; 24:363–7.
5. Huminer D, Garty M, Lapidot M, Leiba S, Borohov H, Ro- senfeld JB. Lymphoma presenting with adrenal insufficiency. *Am J Med* 1988; 84: 169–72.
6. Barzon I, Scaroni C, Sonino N, Fallo F, Gregianin M, Boscaro M, et al. Incidentally discovered adrenal tumors: endocrine and scintigraphic correlates. *Jclin Endocrinol Metab* 1998; 83: 55–62.

7. Kin Stt, Brennan MF, Russo P. The role of surgery in the treatment of clinically isolated adrenal metastasis. *Cancer* 1998;82:389-94.
8. Aron E, Jobard P, Groussin P, Jankowski JM. Lympho-sar- come bilatéral et primitif des glandes surrénales. *Sem Hop Paris* 1971; 47: 3067-71.
9. Oppong F.C., Brodribb A.J., Hunt A.L., Ring N.E. Bilateral adrenal lymphoma presenting as Addison's disease and hypercalcaemia. *Eu.r J. Surg. Oncol.*, 1991, 17, 395-396.
10. Salvatore JR, Ross R. Primary bilateral adrenal lymphoma. *Leuk Lymphoma* 1999;34:111-7.
11. Priou A, Doullay F, Dutour A, Henri JF, Codaccioni JL. Lym- phome bilatéral des surrénales: une cause rare d'insuffisance surrénale. *Presse Med* 1991; 20: 2162-3.
12. Wang J., Sun N.C., Renslo R., Chuang C.C, Tabbarah H.J., Barajas L., French S.W. Clinically silent primary adre- nal lymphoma : a case report and review of the literature. *Am. J. Hematol.*, 1998, 58, 130-136.
13. Maugendre D., Derrien C., Grulois I., Simon J.P, Guil- Hem I., Poirier J.Y., Lerrise P.Y, Allanic H. Lymphome primitif des surrénales avec insuffisance surrénalienne latente : à propos d'un nouveau cas et revue de la littérature. *Ann. Endocrinol. (Paris)*, 1998, 59, 34-39.
14. Tazi K., Achour A., Koutani A., Ibnatty A., Hachimi M., Lakrissa A. Localisation primitive d'un lymphome malin non Hodgkinien de la surrénale. A propos d'un cas. *Revue de la littérature. Progrès en urologie* 1999, 9, 1102-1105.
15. May F., Bachor R., Hack M., Gottfried H.W, Haut- Mann R.E. Primary adrenal non-Hodgkin's lymphoma: long-term survival. *J. Urol.*, 1998, 160, 487
16. Al-Fiar F.Z., Pantalony D., Shepherd F. Primary bilateral adrenal lymphoma. *Leuk. Lymphoma*, 1997, 27,43-549.
17. Cachat M. et al. Lymphome surrénalien primaire bilatéral. *Schweiz Med. Wochen schr.*, 2000, 130, 1120-1124.
18. Chan JKC, et al. Anaplastic large cell lymphoma: Redefining its morphologic spectrum and importance of recognition of the ALK positive subset. *Adv Anat Pathol* 1999; 5: 281-313.
19. Clavio M, Rossi E, Truinini M, et al. Anaplastic large cell lymphoma: A clinico pathologic study of 53 patients. *Leuk lymphoma* 1996; 22: 319-27.
20. Haab F, Duclos JM, Julien J, Plouin PF. Tumeur des deux surrénales : 12 cas consécutifs. *Presse Med* 1994; 23: 511-4.
21. Prinz RA, Brooks MH, Churchill R, Graner JL, Lawrence AM, Paloyan E, et al. Incidental asymptomatic adrenal mas- ses detected by computed tomographic scanning. *JAMA* 1982; 248:701-4.
22. Wu H.C. et al. A patient with bilateral primary adrenal lymphoma, presenting with fever of unknown origin and achieving long-term disease-free survival after resection and chemotherapy. *Ann. Hematol.*, 1999, 78, 289-292.
23. Yamamoto E., Ozaki N., Nakagawa M., Kimoto M. Primary bilateral adrenal lymphoma associated with idiopathic thrombocytopenic purpura. *Leuk. Lymphoma*, 1999, 35, 403-408.
24. Wang J, Sun NCJ, Renslo R, Chvang CC, Tabbarah HJ, Ba- rajas L, et al. Clinically silent primary adrenal lymphoma: a case report and review of the literature. *Am J Hematol* 1998; 58: 130- 6.
25. Al-Fiar FZ, Pantalony D, Sheperd F. Primary bilateral adre- nal lymphoma. *Leuk Lymphoma* 1997; 27: 543-9.